

## ALTERED LIVER MORPHOLOGY AFTER SUB-ACUTE, SUB-CHRONIC AND CHRONIC ORAL ADMINISTRATION OF NEEM OIL IN ALBINO RATS

Zahid Ali Kaimkhani<sup>1</sup>, Syed Naemul Hassan Naqvi<sup>2</sup>, Masood Ahmed Shaikh<sup>3</sup>, Naushin Malik<sup>4</sup>, and Mohammad Rashid<sup>5</sup>

<sup>1</sup>Baqai Medical University, Karachi, Pakistan

<sup>2</sup>Department of Comparative Anatomy and Pharmacology, Baqai Institute of Pharmaceutical Sciences, Karachi

<sup>3</sup>Department of Anatomy and Histology, Qassim University, KSA.

<sup>4</sup>Baqai Institute of Pharmaceutical Sciences, Karachi, Pakistan

<sup>5</sup>Department of Anatomy, Baqai Medical University, Karachi, Pakistan.

---

### ABSTRACT

This research was undertaken to observe the subacute, subchronic and chronic effects of Neem oil on liver morphology and function after oral administration. Ninety six albino rats were used in this study with an equal ratio of male and females. The animals were administered with three different doses of neem oil orally daily for a period of three, six, twelve and twenty four weeks.

The animals were divided in 4 different groups and each group was further divided into 4 subgroups on the basis of duration. Animals were sacrificed at the end of the experimental period. The liver was observed for gross and microscopic findings and the serum levels of liver enzymes, cholesterol and total proteins were studied

Mild liver injuries were recorded in animals treated for 12 and 24 weeks. Biochemical parameters were unaffected except total serum protein levels in animals treated for 12 and 24 weeks. HPLC has demonstrated the presence of low concentration of neem compounds in serum indicating a bio-degradation and tissue utilization.

This study has shown a dose and duration dependent mild toxic effects of neem oil on liver.

**Key-words:** Neem oil, chronic toxicity, liver, histology, enzymes

---

### INTRODUCTION

Toxicity is defined as every harmful effect of a chemical or a drug on a target organism. There is no such thing as a totally safe chemical. The oxygen we breathe is extremely toxic to us and when the concentration is raised 5-fold (Hayes, 1982). Exposure to chemical can be divided into acute, sub acute, sub chronic and chronic. Acute exposure is defined as exposure to a chemical for less than 24 hours. Sub acute, sub chronic and chronic are types of toxicity on the basis of repeated exposure to a chemical. Sub acute toxicity means repeated exposure to a chemical for one month or less, sub chronic for one to three months and chronic for more than three months (Hayes, 1982).

Since the dawn of human, man has depended upon nature's blessing and plants are part and parcel of human society to combat disease. *Azadirachta indica* A. Juss is a medicinal plant generally known as the Neem tree and is kept at bay from the regular dwelling places. It is a native of Myanmar and Indo-Pakistan. In the Indo-Pak this fascinating tree is known for almost last 5000 years and famous as a magical plant and village dispensary. It is also found in Bangladesh, Sri Lanka and African countries as well (Naqvi, 1998).

Over the period of last few decades Neem and its compounds have been studied extensively for various therapeutic purposes and many beneficial results have been reported by various researchers (Chopra *et al.*, 1958; Thakur *et al.*, 1981; Schmutterer *et al.*, 1981; Koul *et al.*, 1990; Chatterjee and Pakrashi, 1994; Jacobson, 1995; Naqvi, 1998; 2006; Yin *et al.*, 2006; Shaikh *et al.*, 2009a and b) but it's possible toxic and sub toxic effects over long term use have not been studied well though few studies on its acute and subacute toxicity are available (Gandhi *et al.*, 1988; Lai *et al.*, 1990; Ibrahim *et al.*, 1992; Chinnnasamy *et al.*, 1993; Jacobson., 1995; Raizada *et al.*, 2001; Srivastava and Raizada, 2001; Reutemann and Ehrlich, 2008; Wang *et al.*, 2013; Deng *et al.*, 2013).

This study was design to investigate the effects of chronic administration of neem oil on liver morphology in albino rats of Wistar strain.

## MATERIALS AND METHODS

Fresh neem oil was obtained from Hussein Ebrahim Jamal Research Institute of Chemistry (H. E. J. R. I. C), Karachi University, Pakistan. The material was stored in a closed container in a cool dry place.

Ninety six adult albino rats of Wistar strain were obtained from the animal house, Baqai Medical University (BMU), Karachi. These albino rats (150-200 g) were housed in the central animal house in separate cages with paddy husk bedding and maintained on standard pellet diet and drinking water ad-libitum until the time of use.

Throughout the experiment, husk beddings were renewed every 3-4 days. The animal room was maintained at 22 to 30 centigrade and with a 12:12 light-dark cycle. Animals were randomly allotted into four experimental groups. After drug administration, free access to food and water was allowed.

### GROUPS

#### Low Dose

A<sub>1</sub> = 6 Rats      A<sub>2</sub> = 6 Rats  
A<sub>3</sub> = 6 Rats      A<sub>4</sub> = 6 Rats

#### Medium Dose

B<sub>1</sub> = 6 Rats      B<sub>2</sub> = 6 Rats  
B<sub>3</sub> = 6 Rats      B<sub>4</sub> = 6 Rats

#### High Dose

C<sub>1</sub> = 6 Rats      C<sub>2</sub> = 6 Rats  
C<sub>3</sub> = 6 Rats      C<sub>4</sub> = 6 Rats

#### Control

D<sub>1</sub> = 6 Rats      D<sub>2</sub> = 6 Rats  
D<sub>3</sub> = 6 Rats      D<sub>4</sub> = 6 Rats

Twenty four animals were administered neem oil with dose of 0.5ml/Kg/day orally (low dose) and were assigned as group A<sub>1</sub>, A<sub>2</sub>, A<sub>3</sub> and A<sub>4</sub>. In group B (medium dose), 24 animals were administered neem oil with dose of 1.0 ml/Kg/day orally and were assigned as group, B<sub>1</sub>, B<sub>2</sub>, B<sub>3</sub> and B<sub>4</sub>. In group C (high dose), 24 animals were administered with dose of 2.0 ml/Kg/day orally neem oil orally and were assigned as group, C<sub>1</sub>, C<sub>2</sub>, C<sub>3</sub> and C<sub>4</sub>. In group D (control), 24 animals were given peanut oil with dose of 2.0 ml/Kg/day orally and were assigned as group, D<sub>1</sub>, D<sub>2</sub>, D<sub>3</sub> and D<sub>4</sub>.

#### GROUP A<sub>1</sub>, B<sub>1</sub>, C<sub>1</sub>, and D<sub>1</sub> (3 week)

All 24 animals (12 male and 12 females) albino rats were scarified at the end of 3 week of treatment.

#### GROUP A<sub>2</sub>, B<sub>2</sub>, C<sub>2</sub>, and D<sub>2</sub> (6 week)

All these 24 animals (12 male and 12 females) albino rats were scarified at the end of 6 week of treatment.

#### GROUP A<sub>3</sub>, B<sub>3</sub>, C<sub>3</sub>, and D<sub>3</sub> (12week)

All these 24 animals (12 male and 12 females) albino rats were scarified at the end of 12 week of treatment.

#### GROUP A<sub>4</sub>, B<sub>4</sub>, C<sub>4</sub>, and D<sub>4</sub> (24 week)

All these 24 animals (12 male and 12 females) albino rats were scarified at the end of 24 week of treatment. At the end of experiment the animals were anesthetized by deep ether anesthesia. Blood removed from the heart by intracardiac puncture (Allen *et al.*, 2001) and then sacrificed (Inauwa and Williams, 1995). Liver, from female and male rats from all groups were removed and fixed in 37% formaldehyde for microscopy (Culling, 1974).

In this chronic study animal mortality was observed. Animals died during experiment were replaced and replacement animals were used.

### MICROSCOPY

For histopathological studies, the liver were removed carefully, weighed and after being observed for any macroscopic changes were preserved in 10 % buffered formal saline (100ml 40% formaldehyde and 900ml of normal saline) . The tissues were routinely processed, embedded in paraffin, sectioned at 5µm. Hematoxylin and Eosin sections were prepared as described by Bancroft and Gamble (2002).

Whole-slide digital scans of all glass slides were created with a Scan Scope scanner (Aperio Technologies, Inc.). Tissues were evaluated for any evidence of organ damage, toxicity or inflammation. Pathological changes were graded according to the severity from mild, moderate to severe and confirmed by experience pathologist.

### BIOCHEMISTRY ANALYSIS

Blood removed from the animals by intracardiac method was centrifuged at 2000 revolution per minute (RPM) to separate the serum. The serum level of Aspartate aminotransaminase (AST), Alanine transaminase (ALT), alkaline phosphatase, total proteins and cholesterol were estimated at the end of experimental period.

### QUANTIFICATION BY HIGH PERFORMANCE LIQUID CHROMATOGRAPHY (HPLC)

During this research 2695 Water Alliance system, having binary pump system, connected with 2487 UV detector and fitted with auto sampler, Zorbax C18, 4.6x150 mm, a reversed phase column was used. The empower software was used to proceed analysis.

### Sample Preparation

One ml of the serum was taken in centrifuge tube and added 1 ml of the acetonitrile, 1 ml of internal standard was added to the same centrifuge tube, 1 ml of precipitating reagent was also added to the centrifuge tube. Sample was sonicated for the 10 minutes and mechanically shook for 15 minutes. Centrifuged at 13000 RMP for 15 minutes, used the supernatant solution, and filtered through 0.45µm Acrodisc syringe filter, directly in to HPLC amber vial for HPLC analysis (Ramesh and Balasubramanian, 1999; Mahmoud *et al.*, 2011).

### STATISTICAL ANALYSIS

All results were expressed as mean  $\pm$  SD for the indicated number of experiments. Statistical analysis was performed by SPSS software version 22.0. The data was analyzed using one-way analysis of variance. The p value less than 0.05 was considered as significant.

## RESULTS

### BIOCHEMICAL ANALYSIS

#### Serum Alanine Aminotransferase

Mean serum levels of ALT in rats, both control and treated with low, medium and high doses of neem oil and scarified at 3 , 6 , 12 and 24 weeks of treatment are shown in table 1. No statistically significant difference was noted in any of the treated groups with dose and duration when compared with control groups and within different treated groups ( $P > .005$ ).

Table 1. Comparison of Means of Serum Alanine Aminotransferase (IU/L) Between Control and Treated Animals.

WEEKS	Low Dose (Mean $\pm$ SD)	Medium Dose (Mean $\pm$ SD)	High Dose (Mean $\pm$ SD)	Control (Mean $\pm$ SD)	p-Value
3	75.50 $\pm$ 12.13	79.00 $\pm$ 11.76	79.33 $\pm$ 16.08	77.16 $\pm$ 5.84	P>0.05
6	78.83 $\pm$ 19.75	76.00 $\pm$ 16.99	76.50 $\pm$ 14.77	78.50 $\pm$ 12.03	P>0.05
12	76.83 $\pm$ 12.12	67.50 $\pm$ 22.68	78.00 $\pm$ 19.03	80.33 $\pm$ 23.10	P>0.05
24	83.83 $\pm$ 17.89	82.83 $\pm$ 10.51	86.83 $\pm$ 28.78	79.33 $\pm$ 17.37	P>0.05

#### Serum Aspartate Transaminase

Mean serum levels of AST in rats, both control and treated with low, medium and high doses of neem oil and scarified at 3 , 6 , 12 and 24 weeks of treatment are shown in table-2. No statistically significant difference was noted in any of the treated groups with dose and duration when compared with control groups and within different treated groups ( $P>0.05$ ).

#### Serum Alkaline Phosphatase

Mean serum levels of ALP in rats, both control and treated with low, medium and high doses of neem oil and scarified at 3 , 6 , 12 and 24 weeks of treatment are shown in table 3. No statistically significant difference was noted in any of the treated groups with dose and duration when compared with control groups and within different treated groups ( $P>.005$ ).

Table 2. Comparison of Means of Serum Aspartate Transaminase (IU/L) Between Control and Treated Animals.

WEEKS	Low Dose (Mean± SD)	Medium Dose (Mean± SD)	High Dose (Mean± SD)	Control (Mean± SD)	p-Value
3	251.17±28.03	256.16± 4.79	251.83±39.36	262.33±34.42	P>0.05
6	249.50±29.20	250.50±33.92	283.00±25.03	245.17±31.19	P>0.05
12	234.17±26.37	277.00±42.27	266.16±42.26	256.16±49.18	P>0.05
24	286.00±48.32	295.00±54.56	270.33±39.76	268.00±43.25	P>0.05

Table 3. Comparison of Means of Serum Levels of Alkaline Phosphatase (IU/L) between Control and Treated Animals.

WEEKS	Low Dose (Mean± SD)	Medium Dose (Mean± SD)	High Dose (Mean± SD)	Control (Mean± SD)	p-value
3	247.16±43.24	225.00± 1.93	235.33±20.45	240.50±19.36	P>0.05
6	263.66±14.55	244.00±31.88	254.66±26.19	254.33±16.31	P>0.05
12	256.50±26.43	245.66±22.49	252.66±31.92	253.33±43.35	P>0.05
24	264.00±36.03	253.50±37.97	239.00±46.39	253.66±38.20	P>0.05

### Serum Cholesterol

Mean serum cholesterol level in rats, both control and treated with low, medium and high doses of neem oil and scarified at 3 , 6 , 12 and 24 weeks of treatment are shown in table 4. No statistically significant difference was noted in any of the treated groups with dose and duration when compared with control groups and within different treated groups (P>.05).

Table 4. Comparison of Means of Serum Cholesterol (mmol/L) between Control and Treated Animals.

WEEKS	Low Dose (Mean± SD)	Medium Dose (Mean± SD)	High Dose (Mean± SD)	Control (Mean± SD)	p-Value
3	0.75±0.15	0.68± 0.20	0.76±0.22	0.77±0.16	P>0.05
6	0.77±0.27	0.76±0.27	0.75±0.29	0.74±0.20	P>0.05
12	0.76±0.18	0.71±0.23	0.64±0.25	0.78±0.38	P>0.05
24	0.74±0.34	0.63±0.29	0.79±0.42	0.77±0.36	P>0.05

### Serum Total Protein

Mean serum total protein level in rats, both control and treated with low, medium and high doses of neem oil and scarified at 3 , 6 , 12 and 24 weeks of treatment are shown in table 5. The serum total protein levels at 3 and 6 week in all treated animals at all doses were statistically non significant (P>0.05) when compared to control and within different treated groups (Table 5).

The serum total protein levels were statistically significant at high dose at 12 week and in all treated animals at all doses at 24 weeks groups (P<0.05) when compared to control an within different treated groups (Table 5)

Table 5. Comparison of Means of Serum Total Protein (g/L) Between Control and Treated Animals.

WEEKS	Low Dose (Mean± SD)	Medium Dose (Mean± SD)	High Dose (Mean± SD)	Control (Mean± SD)
3	70.16±6.55	67.50± 11.53	61.16±5.03	73.00±4.56
6	70.66±6.88	67.33±11.81	61.83±4.07	71.00±4.14
12	69.66±9.28	65.16±8.42	59.50±3.37*	73.00±3.79
24	62.33±7.03*	59.00±6.54*	57.83±3.92*	73.16±6.67

\* p-value is statistically significant (p<0.05)

### Body Weights

Mean body weights and liver weight of control and treated rats with low, medium and high doses of neem oil; scarified at 3, 6, 12 and 24 weeks of treatment are shown in table 6 and 7 respectively. The body weight at 3, 6 and 24 week in all treated animals at all doses were statistically non significant ( $P>0.05$ ) when compared to control (Table-6). While the body weights were statistically significant ( $P<0.03$ ) at 12 week when compared to control (Table-6). The weight of the liver was significantly lower in groups treated with medium and high doses ( $p<0.01$ ) when compared with control group (Table 7).

Table 6. Comparison of Mean Weights (g) in Treated and Control Rats.

	N	Weight (g) Mean $\pm$ SD	p-value
Base line			
Low Dose (A)	24	227.0 $\pm$ 28.4	0.09
Medium Dose (B)	24	200.1 $\pm$ 22.7	
High Dose (C)	24	185.4 $\pm$ 39.4	
Control (D)	24	217.3 $\pm$ 58.1	
At 3 week			
Low Dose (A)	24	236.0 $\pm$ 38.7	0.09
Medium Dose (B)	24	205.8 $\pm$ 39.6	
High Dose (C)	24	191.4 $\pm$ 49.0	
Control (D)	24	225.4 $\pm$ 78.3	
At 6 week			
Low Dose (A)	18	252.0 $\pm$ 43.0	0.16
Medium Dose (B)	18	227.2 $\pm$ 42.5	
High Dose (C)	18	203.1 $\pm$ 45.0	
Control (D)	18	261.3 $\pm$ 54.1	
At 12 week			
Low Dose (A)	12	264.3 $\pm$ 48.3	0.03
Medium Dose (B)	12	255.8 $\pm$ 43.9	
High Dose (C)	12	214.1 $\pm$ 43.7	
Control (D)	12	290.5 $\pm$ 59.6	
At 24 week			
Low Dose (A)	6	292.8 $\pm$ 72.1	0.562
Medium Dose (B)	6	290.0 $\pm$ 65.8	
High Dose (C)	6	260.8 $\pm$ 42.5	
Control (D)	6	327.8 $\pm$ 74.2	

### HPLC

The chromatogram 1 of treated rats with high dose at 3 week (C<sub>1</sub>), the area of peak is 19837  $\mu\text{m}$  at 0.630 minutes (chromatogram 1, C<sub>1</sub>). The 2<sup>nd</sup> peak (neem oil) has an area of 77823  $\mu\text{m}$ , indicating more intake of neem oil after 3 weeks. No 3<sup>rd</sup> peak is present in this chromatogram (Plate-1).

The chromatogram 2 of treated rats with high dose ( $C_2$ ) after 6 weeks shows the 1<sup>st</sup> peak at 0.632 minutes with area as 6219  $\mu\text{m}$  while the 2<sup>nd</sup> peak is at 0.931 minutes with an area of 6679  $\mu\text{m}$  which is less than the earlier chromatogram. With passage of time the quantity of the solvent and neem oil is decreasing (Plate-2).

In the next chromatogram 3 of treated rats with high dose ( $C_3$ ) after 12 week, the 1<sup>st</sup> peak is at 0.63 minutes and the area of peak is 6137 while the 2<sup>nd</sup> peak of neem oil is at 0.912 minutes and the area of peak is 76622  $\mu\text{m}$  (Plate-3). The chromatogram 4 of treated rats with high dose ( $C_4$ ), the solvent peak is 0.625 minutes with peak area 4616  $\mu\text{m}$  while the Neem oil peak appeared after 0.358 minutes with an area of 25599  $\mu\text{m}$  after 24 weeks. It shows further reduction in peak area due to excretion or biodegradation (Plate-4).

Table 7. Comparison of mean liver weights (g) in treated and control rats.

	N	Weight (g) Mean $\pm$ SD	p-value
Low Dose (A)	24	9.50 $\pm$ 0.9	0.01
Medium Dose (B)	24	8.9 $\pm$ 1.9	
High Dose (C)	24	8.4 $\pm$ 1.4	
Control (D)	24	10.2 $\pm$ 1.8	

### HISTOLOGY OF LIVER

Examination of the liver from both control and treated groups showed intact architecture (Fig.1). Treated groups, however, revealed some histological changes. These include congestion, perivenular (zone III) swelling and vacuolization of the hepatocytes in treated animals at 12 and 24 weeks. The changes were mild in group B (medium dose) while they were initially mild but approached to moderate in group C (high dose) (Fig.2). Treated group A (low dose) did not show any changes even at week 24 (Fig.3). There was no evidence of lobular or portal inflammation, lobular necrosis or apoptosis, enlargement or stenosis of sinusoids, kupffer cell prominence or bile duct injury or proliferation in any of the animals in any groups.

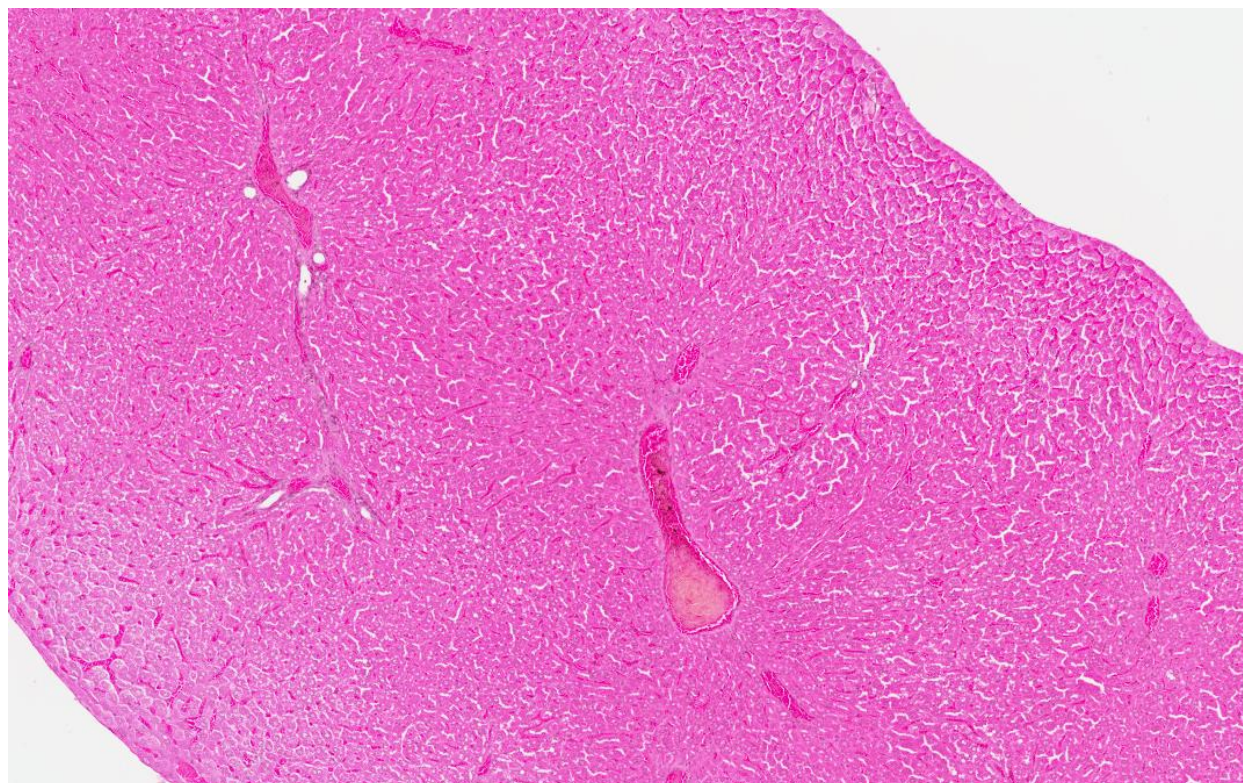


Fig.1. Photomicrograph, of a 5  $\mu\text{m}$  thick horizontal section of the liver from a control group animal showing, normal hepatic lobular pattern with centrilobular veins, hepatic sinusoids and portal triad structures. Original magnification 5X (H & E)



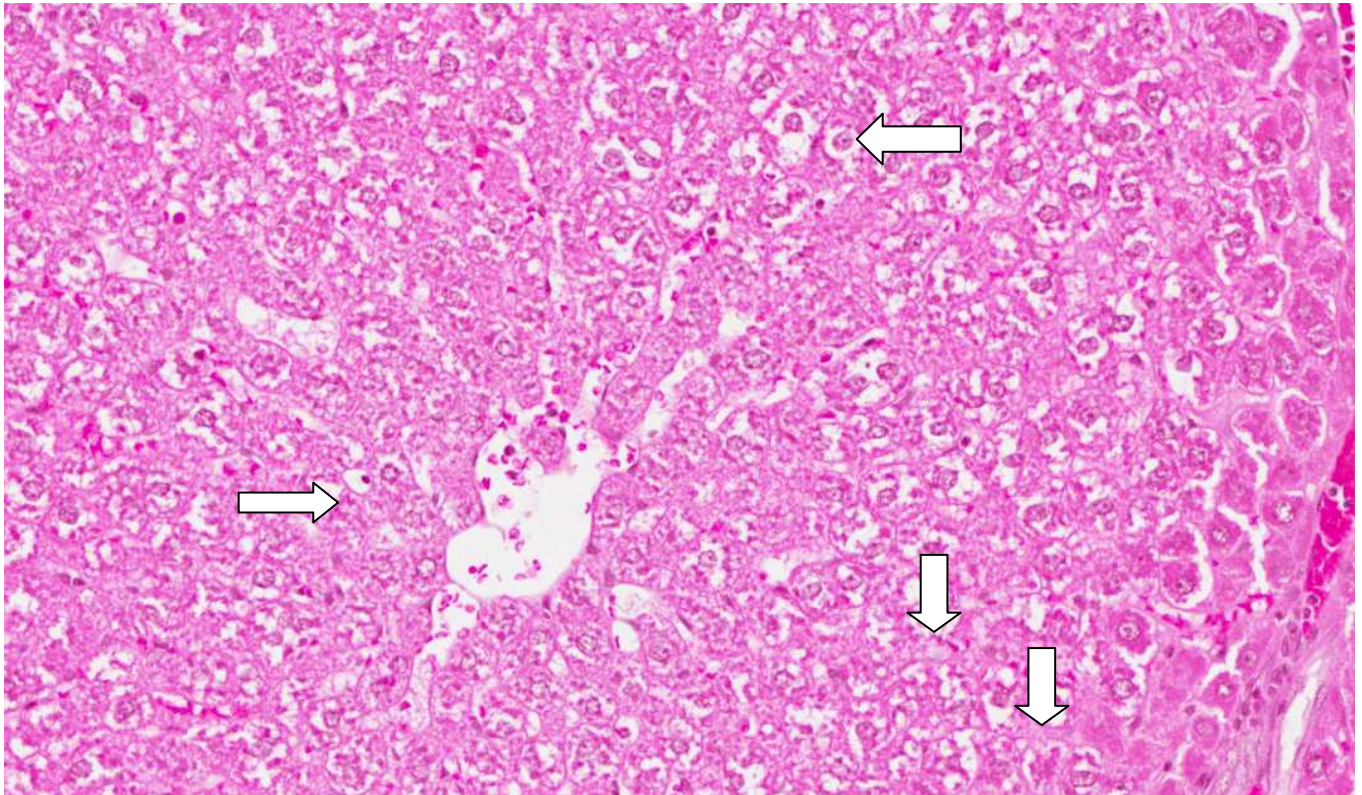


Fig.2. Photomicrograph, of a 5  $\mu$ m thick horizontal section of the liver from a treated animal with high dose at 24 week showing perivenular hepatocytic swelling and vacuolization.(white arrows).Original magnification 20X (H & E)

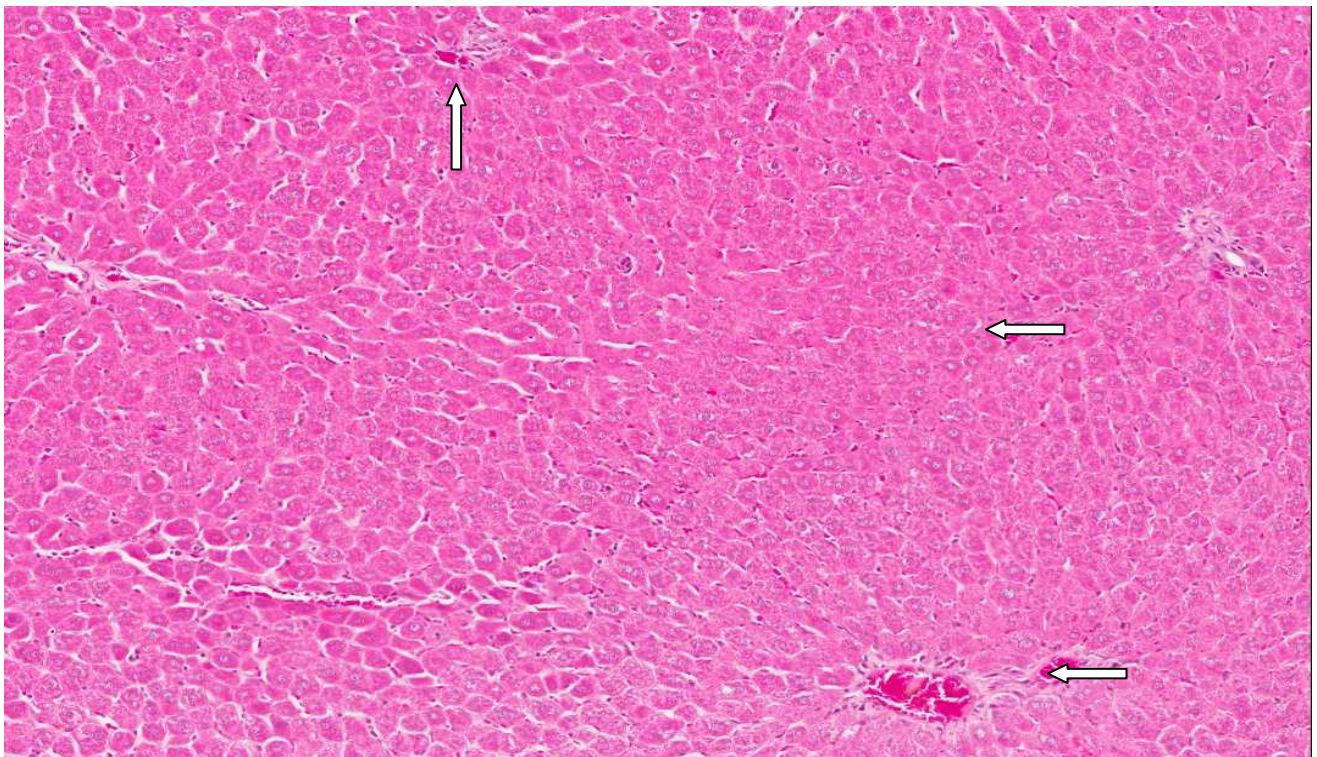


Fig.3. Photomicrograph of a 5  $\mu$ m thick horizontal section of the liver from a treated animal with low dose at 12 weeks showing congestion. (Arrows) Original magnification 10X (H & E)



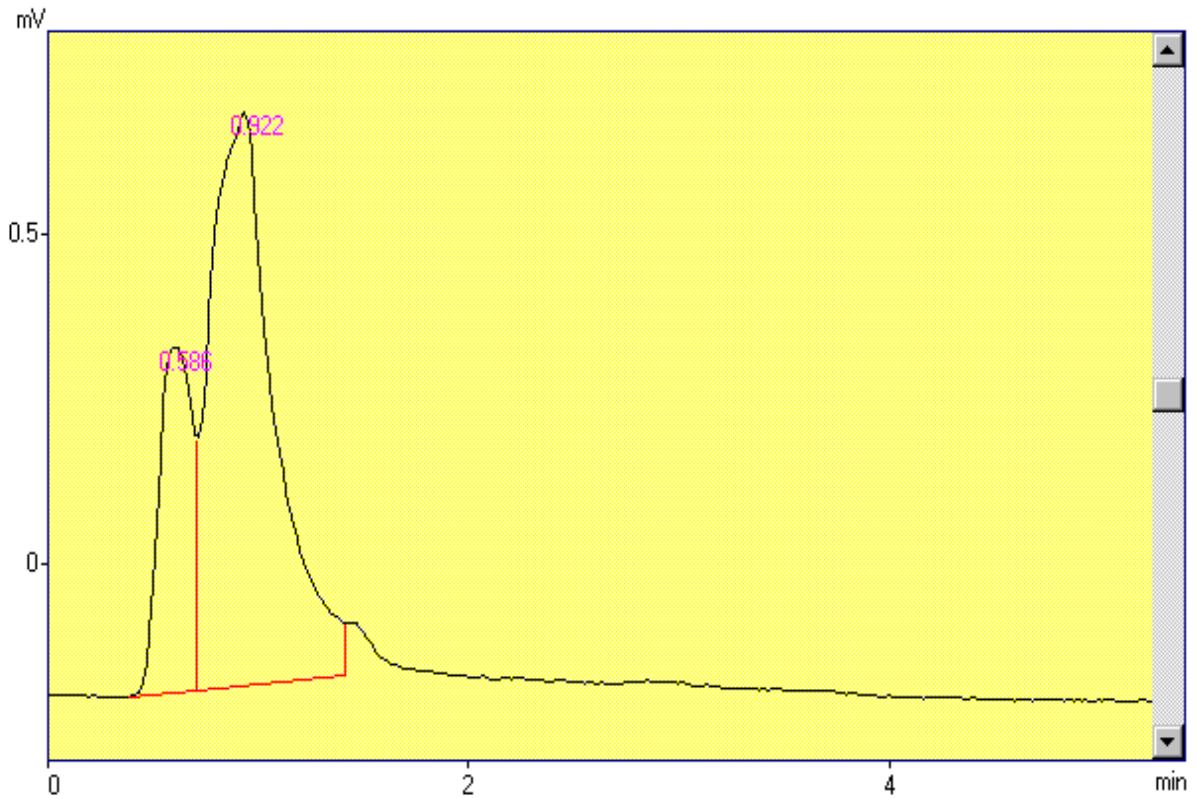


PLATE 1. NEEM OIL EXTRACTED WITH ACETONITRILE, CHROMATOGRAMS OF GROUP C1 (High Dose at 3 week).

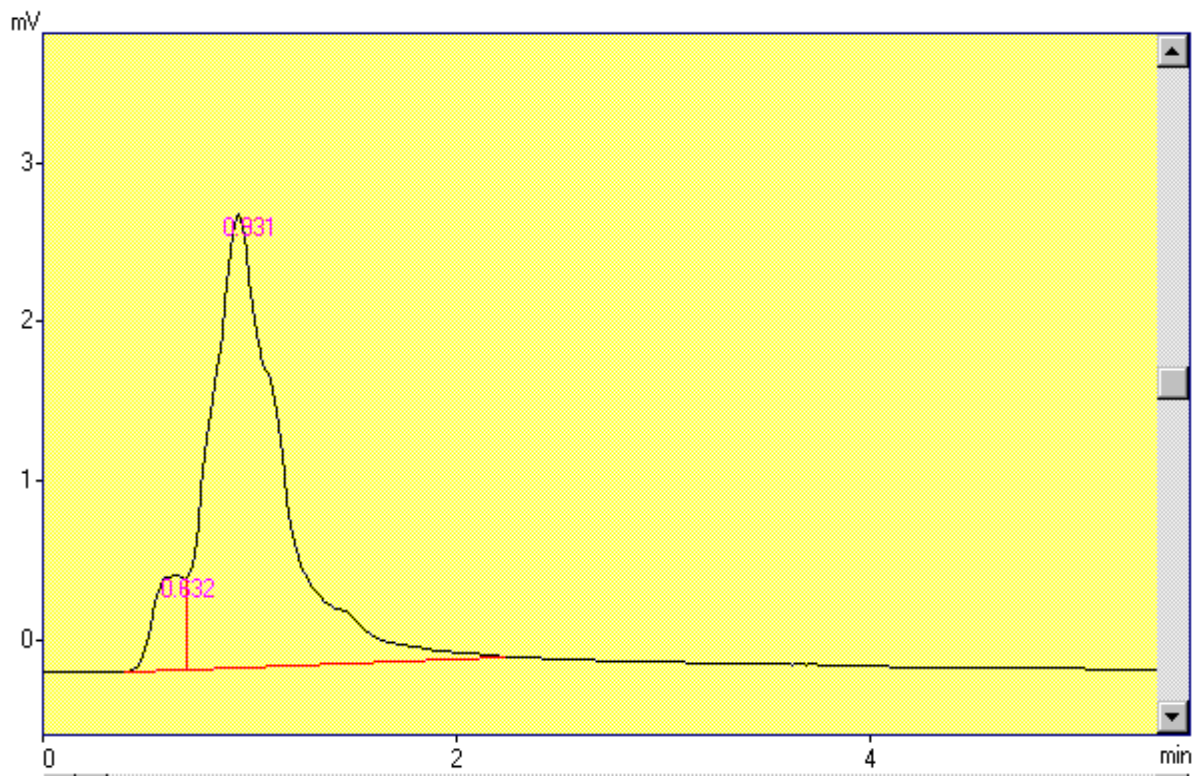


PLATE 2. NEEM OIL EXTRACTED WITH ACETONITRILE, CHROMATOGRAMS OF GROUP C2 (High Dose at 6 week)



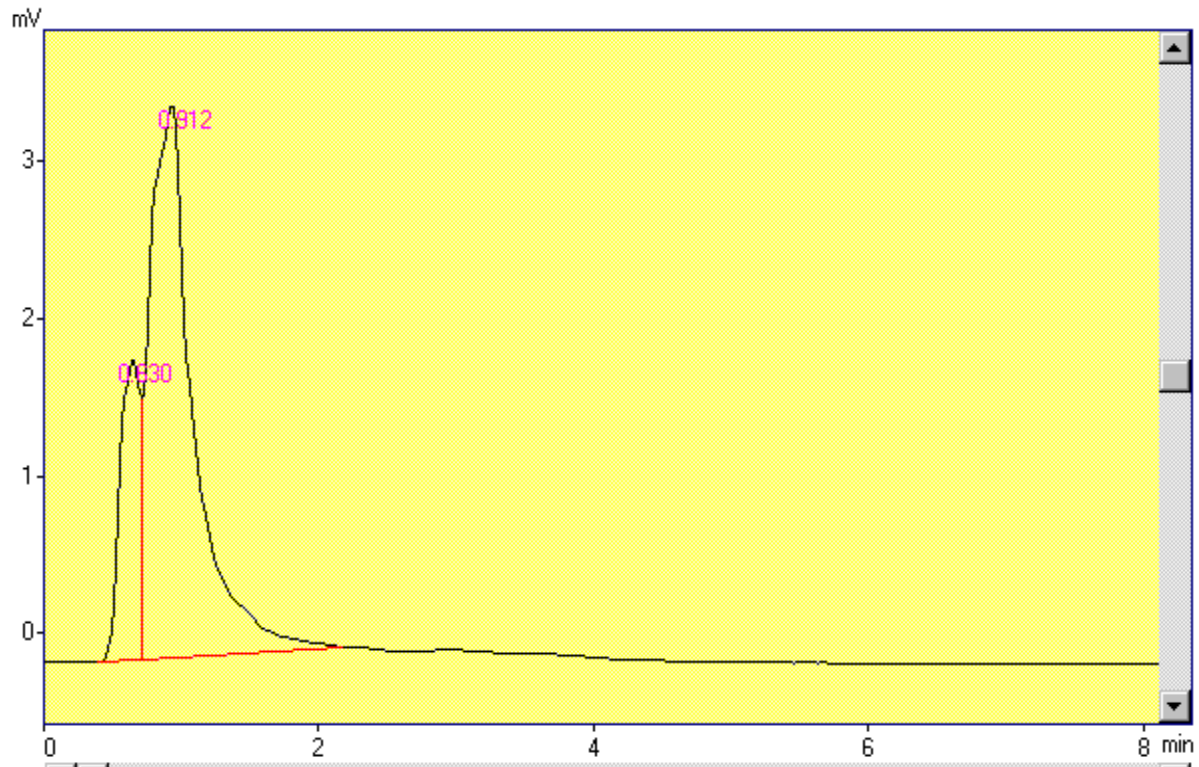


PLATE 3. NEEM OIL EXTRACTED WITH ACETONITRILE, CHROMATOGRAMS OF GROUP C (High Dose at 12 week).

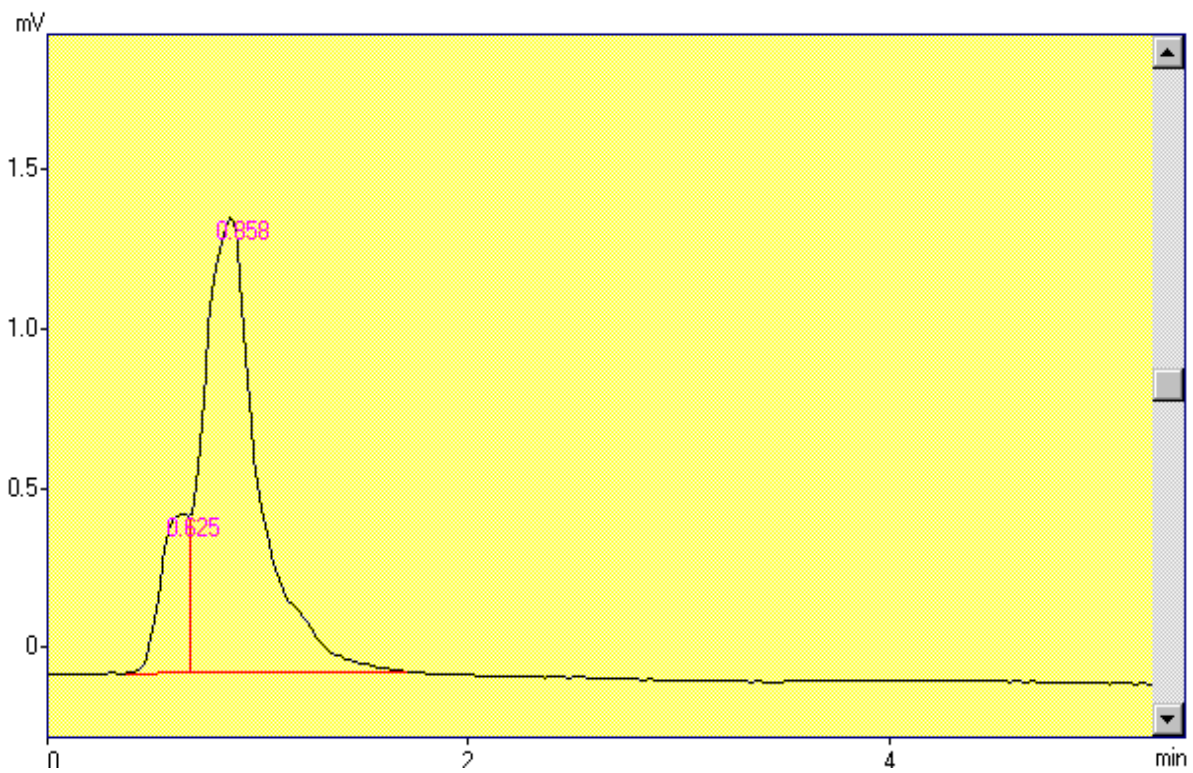


PLATE 4. NEEM OIL EXTRACTED WITH ACETONITRILE, CHROMATOGRAMS OF GROUP C4 (High Dose at 24 week).

Peaks report (Plate 1)

Peak No	TIME(min)	AREA( $\mu$ m)
1	0.586	19837
2	0.922	77823
TOTAL		97660

Peaks report (Plate 2)

Peak No	TIME(min)	AREA	HEIGHT	CONC
1	0.632	6219	599	8.5436
2	0.931	66572	2859	91.4564
TOTAL		72791	3458	100.0000

Peaks report (Plate 3)

Peak No	TIME(min)	AREA	HEIGHT	CONC
1	0.630	6137	1914	9.7787
2	0.912	56622	3511	90.2213
TOTAL		62759	5425	100.0000

Peaks report (Plate 4)

Peak No	TIME(min)	AREA	HEIGHT	CONC
1	0.625	4616	498	15.2772
2	0.858	25599	1430	84.7228
TOTAL		30215	1928	100.0000

## DISCUSSION

Mammalian organ systems work in great harmony, they are interdependent structurally and functionally therefore to obtain the full therapeutic benefit of a pharmacologic agent maximum natural interplay amongst them is needed. According to the findings of our study the weights of animals (Table 6) and organ weight of liver did not show any significant change when compared to their controls in any of the group in this study (Table 7). Gross features and consistency of the liver was also normal. Microscopic architecture and the arrangement of the cellular and vascular tissue in the liver were almost within normal range in the animals given a low and a medium dose in this study. Animals, which received a high dose for a period of twelve week has shown a mild congestion, (Fig. 2) while the animals treated for 24 weeks have shown a higher degree of congestion with peri-centriolar hepatocytic swelling (Fig. 2).

These finding are consistent with the finding of Wang *et al.*, (2013) and Deng *et al.*, (2013), who have reported similar findings after an experimental period. The biochemical parameters for the functional assessment of the liver including AST, ALT, ALP, Total proteins and cholesterol were within normal range in the experimental animals treated for three and six week (Table 1-5) Ours, these findings are in agreement with the findings of Mallick *et al.*, (2013) who have reported no significant change in the structure and function of liver after an experimentation of 4 week in mice. Animals treated for 12 and 24 weeks in this study, have shown a decrease in serum total proteins levels. HPLC findings of this study have shown that with increasing dose and duration of the experiment, peaks

produced by neem are declining in area signifying that higher quantities of neem compounds were consumed by the tissues and lesser amounts were present in the serum.

Wang *et al.*, (2013) have reported liver damage at a dose of 1600mg/kg/day of Neem oil when administered for 90 days but these changes were reversible within 30 days after terminating the administration of the drug. Correlating the histological and biochemical findings of our study, it signifies that the liver was mildly injured in the animals treated at high dose with slightly affected levels of serum proteins. The possible explanation to this may be that still the functional reserve of the liver was able to compensate the damaged tissue.

## CONCLUSION

The present study concludes that the neem oil produces mild pathological changes in the mammalian liver experimented in this study. The most evident pathological changes were a mild congestion in the liver groups received a high dose for a period of twelve week. Biochemical parameters did not show any significant change except a decline in serum total protein levels at a high dose in 12 weeks and at all doses in 24 weeks treated animals.

## REFERENCES

- Allan, C.M., M. Haywood, S. Soji, A. Spalivero, Koch, M. Jimenez, M. Poutanen, M. J. Levallet, P. Illingworth and D. J. Handelsman (2001). A novel transgenic model to characterize the specific effects of follicle stimulating hormone on gonadal physiology in the absence of Luteinizing Hormone Actions. *Endocrinology*, 142: 62213-20.
- Bancroft, J.D. and M. Gamble (2002). Theory and Practice of Histological Techniques. *Churchill Livingstone*, London. pp.74-83.
- Chinnasamy, N., N. Harishankar, P.U. Kumar, and C. Rukmini (1993). Toxicological studies on debitterized neem oil (*Azadirachta indica*). *Food and Chemical Toxicology*, 31: 297-301.
- Chopra, R.N., I.C. Chopra, K.L. Handa, L.D. Kapur (1958). *Indigenous drugs of India*. U.N. Dhar and Sons Pvt. Ltd., Calcutta, pp. 360.
- Chatterjee, A. and S. Pakrashi (1994). *The Treatise on Indian Medicinal Plants*. vol. 3, National Inst. Science Communication and Information Resources New Delhi, p. 76.
- Culling, C.F.A. (1974). *Handbook of histopathological and histochemical techniques*. 3<sup>rd</sup> edition, Butterworth and Company, London.
- Deng, Y.D., M. Cao, D. Shi, Z. Q. Yin, R. Y. Jia, J. Xu, C. Wang, C. Lv, X. X. Liang, C. L. He, Z. R. Yang and J. Zhao (2013). Toxicological evaluation of neem (*Azadirachta indica*) oil: Acute and subacute toxicity. *Environ Toxicol Pharmacol.*, 35: 240–246.
- Gandhi, M., R. Lal, A. Sankaranarayanan, C. K. Banerjee, P. L. Sharma (1988). Acute toxicity study of the oil from *Azadirachta indica* seed (neem oil). *J Ethnopharmacol.*, 23: 39-51.
- Hayes, A.W. Editor (1982). *Principles and Methods of toxicology*. Raven Press, New York.
- Ibrahim A, S.A. Khalid, S.A. Omer and S.E. Adam (1992). On the toxicology of *Azadirachta indica* leaves. *J Ethnopharmacol.* 35: 267-73.
- Inauwa, I., and M.A. Williams (1995). Morphometric Study of the uterine horn and thyroid gland in hypothyroid and thyroxin treated hypothyroid rats. *J. Anat.*, 188: 383-393
- Jacobson, M. (1995). In: *The Neem Tree: Source of Unique Natural Products for Integrated Pest Management, Medicine, Industry and Other Purposes* (ed. Schmutterer, H.), pp. 484–495.
- Koul, O., M.B. Isman, C.M. Ketkar (1990). Properties and uses of neem, *Azadirachta indica*. *Can. J. Bot.*, 68: 1-11
- Mahmoud, D.A. N.M. Hassanein, K.A. Youssef, M.A. AbouZeid (2011). Antifungal activity of different neem leaf extracts and the nimonol against some important human pathogens. *Braz J Microbiol.*, 42: 1007-16.
- Lai SM, K.W. Lim and H.K. Cheng (1990). *Margosa oil poisoning as a cause of toxic encephalopathy*. *Singapore Med J.*, 31: 463-5.
- Mallick, A., S. Ghosh, S. Banerjee, S. Majumder, A. Das, B. Mondal, S. Barik, K.K. Goswami, S. Pal S, S. Laskar, K. Sarkar, A. Bose and R. Baralb (2013). Neem leaf glycoprotein is nontoxic to physiological functions of Swiss mice and Sprague Dawley rats: Histological, biochemical and immunological perspectives. *Int immunopharmacol.*, 15: 73-83.
- Naqvi, S.N.H. (1998). Pharmacological importance of Neem, *Azadirachta indica* A.Juss (Meliaceae) *J. Baqai Med. Univ.*, 1: 39-50.
- Naqvi, S.N.H. (2006). Biological Evaluation of various neem products and isolated compounds against different animals in Pakistan. *Proceedings of the International Neem Conference*, Kunming, China.



- Raizad,a, R.B., M.K. Srivastava, R.A Kaushak and R.P. Singh (2001). Azadirachtin, a neem biopesticide: subchronic toxicity assessment in rats. *Food and Chemical Toxicology*, 39: 477-483.
- Ramesh. A. and M. Balasubramanian (1999). Rapid preconcentration method for the determination of azadirachtin-A and -B, nimbin and salannin in neem oil samples by using graphitised carbon solid phase extraction. *Analyst*, 124: 19–21.
- Reutemann, P. and A. Ehrlich (2008). Neem oil: an herbal therapy for alopecia causes dermatitis. *Drug* , 19: 12-5.
- Schumutterer,,H., K.R.S. Ascher and H. Rembold (1981). Natural Pesticides from the Neem Tree. *Proc.Int Int.Neem Conf.* (Rottach-Egern, Germany, 1980).
- Shaikh, M.A., S.N.H. Naqvi and Z.A.Kaimkhani (2009-a). Effect of Neem oil on the structure and function of the mature female albino rat ovaries. *Einstein.*, 7: 28-34.
- Shaikh, M.A., S.N.H.Naqvi and M.Z. Chaudhry (2009b). Effect of neem oil on the structure and function of the mature male albino rat testes. *Braz. J. Morphol. Sci.*, 26: 49-54.
- Srivastava, M.K., and R.B. Raizada (2001). Assessment of embryo fetotoxicity and teratogenicity of azadirachtin in rats. *Food and Chemical Toxicology*, 39: 1023–1027.
- Thakur, R.S., S.B.Singh, A.Goswami (1981). *Azadirachta indica* A. Juss: A review. *Current Research in Medicinal and Aromatic Plants*, 3: 135 – 140.
- Wang, C., M.Cao, D.X.Shi, Z.Q.Yin, R.Y.Jia, K.Y.Wang, Y.Geng,Y. Wang,X.P, Yao,Z.R.Yang and J.Zhao (2013.) A 90-day subchronic toxicity study Of neem oil, a *Azadirachta indica* oil, in mice. *Human and Experimental Toxicology*, 1–10.
- Yin, Z.Q., X.S. Zhang and C.K.Wu (2006). Approach on the anti-fertility effect and the mechanism of action of the compound of neem oil on female mice. *Reprod. Contracept.*, 26: 146–147.

(Accepted for publication August 2014)