

EVALUATION OF TOXIC EFFECTS OF *TRIGONELLA FOENUM-GRAECUM* LEAF AQUEOUS EXTRACT ON DEVELOPMENT OF LONG BONE TISSUE IN RAT FETUS

Ziba Mozaffari^{1,2}, Mahnaz Azarnia³ and S. Abdolhamid Angaji^{3,*}

¹Department of Biology, Faculty of Sciences, Islamic Azad University, Hamedan Branch, Hamedan, Iran

²Department of Biology, Faculty of Sciences, Islamic Azad University, Sanandaj Branch, Sanandaj, Iran

³Department of Biology, Faculty of Sciences, Tarbiat Moallem University, Tehran, Iran

* Corresponding author

Email: Ershad110@yahoo.com, Angaji@tmu.ac.ir

ABSTRACT

In the present study, the adverse effects of *Trigonella foenum-graecum* leaves aqueous extract (TGLE) on the organogenesis stage of Sprague-Dawley rat fetus was investigated; particularly, the effect on fetal development of the hind limb long bone. TGLE was administered in pregnant rats by intra peritoneal (i.p.) injection at the dose levels of 0.8, 1.6 and 3.2 (g / kg / day) on the 10th day of gestation. Then all rats were sacrificed on the 20th day of gestation and fetuses were removed from their uterus. The fetuses were assayed for histopathological signs of long bone. The results indicated that the treatment with TGLE (3.2 g /kg /day) were significantly different in long bone structure and growth histology details disorder in comparison with the control group (p<0.001). The treated group showed a correlation with the histopathological changes of long bone tissue in their fetuses. As a consequence, if only TGLE is used without consumption of any herbal plant concurrently, TGLE has toxic potential on pregnant rats at the highest dose level (3.2 g /kg /day). It showed that the extract has adverse effects on the development of hind limb long bone by disorder in the histology details of cell structure and growth into long bone during endochondral ossification. Thus TGLE at the highest dose level may cause severe adverse alterations in rat fetus. Proper clinical research should be carried out to confirm the same activity in human.

Keywords: *Trigonella foenum-graecum* extract; Toxicology; Long bone of rat fetus.

INTRODUCTION

Fenugreek (*Trigonella foenum-graecum* L.) is extensively distributed in most regions of the world and endemic. The genus *Trigonella* belongs to the family Leguminosae, subfamily Papilionaceae. Its seeds and leaves are believed to have not only antidiabetic effects (Shani *et al.*, 1974) but also they have been studied for nutritional (Rajagopalan, 1998; Fazli and Hardman, 1968) and therapeutic (Basch *et al.*, 2003) properties widely in the world. The leaves are consumed widely in India as a green, leafy vegetable and they are a rich source of calcium, iron, *B*-carotene and other vitamins (Sharma, 1986). *Trigonella foenum-graecum* extract is also reported to have immunomodulatory effects in mice (Bin-Hafeez *et al.*, 2003). There are several reports concerning the antinociceptive, anti-inflammatory and anti-pyretic effects of the plant. *Trigonella foenum-graecum* under the name of “*Shanbalileh*” in Iranian is traditional medicine (Mirhaydar, 1994; Zargari, 1992). Previous studies have been showed that aqueous extract of *Trigonella foenum-graecum* leaves, used both orally and intra peritoneal, possesses a hypoglycemic effect in normoglycaemic and in alloxan induced hyperglycemic rats (Abdel-Barry *et al.*, 1997). But according to the previous studies, it has an effect on the pregnancy period through the stimulating effect of estrogen present on the uterus (Khare *et al.*, 1983; AL-Hamood and AL-Bayatti, 1995; Elbetieha *et al.*, 1996). Although there is plenty of evidence that confirms therapeutical effects of *Trigonella foenum-graecum* growing in different parts of the world, few reports are available on the adverse effects of this herbal plant on the fetus. Therefore, the main reason in the current study is to investigate the potential toxicity of *Trigonella foenum-graecum* leaves aqueous extract (TGLE) on the development of long bone in the fetus. Based on our finding, the mentioned-dosage of TGLE is capable of changing the osteogenesis in long bone which may cause severe disorders in to histological details of cell structure and growth of hind limb long bone during endochondral ossification in the rat fetus.

MATERIALS AND METHODS

Plant

The aerial parts of the plant, i.e. green leaf vegetable, were collected at a high elevation of 1110 m during the flowering stage (2006). They were obtained from a farm around Tehran. Then it was scientifically identified and authenticated by the Gh. Amin (Herbarium, faculty of pharmacy, Tehran University of medical sciences, Tehran, Iran) in Jan 2008. The voucher number encoded 6683-TEH of specimen that was the deposited at the herbarium, Department of Pharmacognosy, Faculty of Pharmacy, Tehran University of Medical Sciences.

Preparation of the aqueous extract

The extract was obtained from the pharmacy faculty. The aerial parts of the plant containing fresh and green leaves were separated and cleaned, then dried in the shade at room temperature. The specimens were boiled for 30 minutes and the extract was filtered and concentrated with a rotary evaporator apparatus by strainer. The pure liquid was located in warm bath and its aqueous extract with high viscosity was collected. Just before using it, the extract was diluted in distilled water (DW) at the desired concentration (volume 1.5 ml).

Experimental animals and design

Male and female (200-250g) Sprague-Dawley rats aged 3-4 months (Razi Serum Institute, hesarak, Karaj, Iran) were used. They employed after 1 week of quarantine and acclimatization. The animals were housed in a room with the temperature of $24 \pm 2^{\circ}\text{C}$ and a relative humidity of 45-55% under a well-regulated 12:12 h light/dark cycle. For mating, the animals were randomly divided into four groups of four animals. Then three female rats were placed in a cage with one male rat overnight. Successful mating was confirmed by the presence of sperm in the vaginal smear, and the following 24 h was designated as day 0 of the gestational period (GD0). The mated female rats were housed individually in clear polycarbonate cages. Then they were fed a standard commercial pelleted food diet of "pars dam" company and received water by automatic system.

Pregnant female rats' treatment

The mated female rats (as triplicate into the each group) were administered the following extract dosages: 0.8, 1.6 and 3.2 (g /kg/day) respectively. A group as the control group received 1.5ml of distilled water by intra peritoneum (i.p.) injection, solely once on the 10th day of the gestation during the time of organogenesis initiation and development of limb bud. Then on the 20th day of pregnancy, the rats were anaesthetized and their fetuses were removed from the uterus. After maternity enzymatic levels assay and fetal macroscopic examinations, they (fetuses) were prepared for histological surveys.

Say samples

In group A (control), 2 samples of embryo were randomly selected. They were collected from 3 pregnant rats each. Therefore, there were 6 samples of embryos in each group. The same design was also considered for groups B, C and D (receiver groups of extract, 0.8, 1.6 and 3.2 g /kg /day) respectively.

Preliminary LD50 test

The extract, LD50 was considered as 4.1 g/kg/day; Female Sprague-Dawley rats (as triplicate into the each group) were administered the following extract dosages: 0.8, 1.6 and 3.2 (g /kg/day) respectively. Doses of the extract were separately injected (i.p.) to the first group ($n=3$), to find the dose that kills 50% of the injected animals during the 72 h after the injection.

Sample preparation for light microscopy and histopathological analysis

The fetal long bones were fixed in formalin for 72 hours, and washed by a solution of formic acid 100 ml, chloridric acid 80 ml and distilled water 820 ml for decalcification. Then, they were kept in a solution consisting of formalin 10%, commercial formalin 100cc and in water 900cc. The samples were cut into sections with 5 μm thickness (longitudinally). Then, they were directly dehydrated in graded series of EtOH and embedded in paraffin. It was followed by staining with hematoxylin and eosin (H & E method) for histological examination. The status of TGLE toxicity on the osteogenesis process of hind limb long bones under endochondral ossification details were recorded and scored by a histopathologist. Histopathological damage was scored on a scale of 0-3 (0 – no change, 1 – mild, 2 – moderate, 3 – severe).

Statistical analysis

The results of our experiments were expressed as mean \pm SEM. The macroscopic parameters data were analyzed by one-way ANOVA, followed Tukey HSD post-hoc analysis using SPSS to 11.5 version. Since the histopathological data were qualitative, they did not show normal distribution, and therefore a non-parametric test (N par test) was used to compare the histopathological changes. Thus the mean of data between groups was analyzed by Kruscal Wallis test. The differences were considered significant at $p < 0.05$.

RESULTS

Symptoms due to effect of *Trigonella foenum- graecum* leaf aqueous extract

Fetal macroscopic signs

The effect of TGLE on the macroscopic parameters of rat fetus is shown in Table 1. The Body Weight (BW), Crown Rump (CRL), Bi Parietal Diameter nose tip to occipital (BPD)_n of the rats fetus treated with TGLE (0.8, 1.6 and 3.2 g/kg/day) also Bi Parietal Diameter ear to ear (BPD)_e of the rats fetus treated with TGLE (0.8, 1.6g/kg/day) were not affected in comparison with those of the control group ($P>0.05$), while administration of TGLE (3.2 g/kg/day) was significantly decreased for Bi Parietal Diameter ear to ear (BPD)_e parameter ($P<0.05$) comparison to the control group ($P=0.039$). Also for all macroscopic parameters of the fetus rats were decreased in treatment with TGLE (at just 3.2 g/kg/day) in comparison to the control group. The macroscopic nonparametric observations were not affected by TGLE treatment. It means that no teratogenic signs of anomaly and malformation were observed in the treated groups by TGLE (0.8, 1.6 and 3.2 g/kg/day) during the experimental period.

Table 1. Effect intra paritonal administration of *Trigonella foenum- graecum* leaves aqueous extract (TGLE) at the indicated doses once at 10th day of gestation on macroscopic parameters in fetus rats

Macroscopic Parameters	a	n	b	Control	TGLE (g/ kg/ day)		
					0.8	1.6	3.2
Body weight (g)		6		6.50± 0.03	6.50±0.02	6.45±0.03	6.42±0.03
Crown-rump length (mm)		6		39.40± 0.06	39.40 ±0.06	39.41±0.06	39.38±0.06
Bi-parietal diameter ear to ear (mm)		6		8.02± 0.03	8.01± 0.02	7.97± 0.02	7.94± 0.02
Crown-rump length			6	14.934±0.05	14.937±0.05	14.938±0.06	14.833±0.04
Bi parietal diameter nose tip to occipital (mm)							

a, Abbreviations as for Table 2. *Trigonella foenum- graecum* leaves aqueous extract (TGLE) did not affect the macroscopic parameters in rat fetus at all used dose levels, except for Bi parietal diameter ear to ear (3.2 g/kg/day; i.p. injection; comparison to the control group). b, number of rat fetus in each group. Values are expressed as mean ± SEM. for 24 of the rat fetuses. ** $p < 0.05$ compared with controls. Comparisons were made between control and experimental groups.

Fetal histopathologic signs

Changes of overall histopathology were considered as plus. The status showed no change (-) + mild (+), moderate (++) and severe (+++) for estimation of differences between groups treated with different dosages of TGLE (0.8, 1.6, 3.2 g/kg/day). Also the mean of the changes between the groups for all histopathological factors is shown in Table 2. On the other hand, these trials showed the all osteogenesis histopathological factors of hind limb long bone of rat fetus were significantly higher in the groups treated with TGLE (0.8, 1.6, 3.2 g/kg/day) than those of the control group ($p<0.001$ (Fig. 1). The assessment factors on structure and growth histology details (histopathological changes) of fetus long bone were included: Reduction of mineralization (Rm) +Deformation in bone collar (thin & thick) (Db) +Deformation of growth cartilage plate (Dg) +Narrowing of bone marrow (Nm) and Abnormal long bone form (Al). According of table 2, they were affected by administration of TGLE in all the doses used in comparison with those of the control group ($P<0.05$). So in this study histopathological changes were expressed as qualitative status of mild, mild to moderate and severe in the groups treated by TGLE (0.8, 1.6 and 3.2 g/kg/day) respectively (Fig. 3., B, C and D). Therefore, rat fetus treated with TGLE (3.2 g/kg/day) were significantly decreased for histopathological factors ($p<0.001$; Fig. 3, D) while those were normal in control group (Fig. 2, A).

Table 2. Effect of intra paritonal administration of *Trigonella foenum- graecum* leaves aqueous extract (TGLE) at the indicated doses once at 10th day of gestation on the histopathological signs of rat fetus long bone.

Histopathological signs <i>a</i>	n <i>b</i>	TGLE (g /kg / day)		
		0.8	1.6	3.2
Dg	6	1.16± 0.16*	1.66± 0.21**	2.66± 0.21**
Db	6	1.16± 0.16*	1.50± 0.22**	2.50± 0.22**
Nm	6	1.00± 0.00**	1.16± 0.16**	2.66± 0.21**
Rm	6	1.16± 0.16*	1.66± 0.21**	2.66± 0.21**
Al	6	1.16± 0.16**	1.33± 0.21**	2.83± 0.16**

a, Dg: Deformation of growth cartilage plate; Db: Deformation in bone collar (thin & thick); Nm: Narrowing of bone marrow cavity; Rm: Reduction of mineralization; Al: Abnormal long bone form. *b*, number of rat fetus in each group. Values are expressed as mean ± SEM. for 24 of the rat fetuses. **p* <0.01; ***p* <0.001 compared with controls. Comparisons were made between control and experimental groups. Data were normal (no changes) in control group (0.00±0.00); n=6

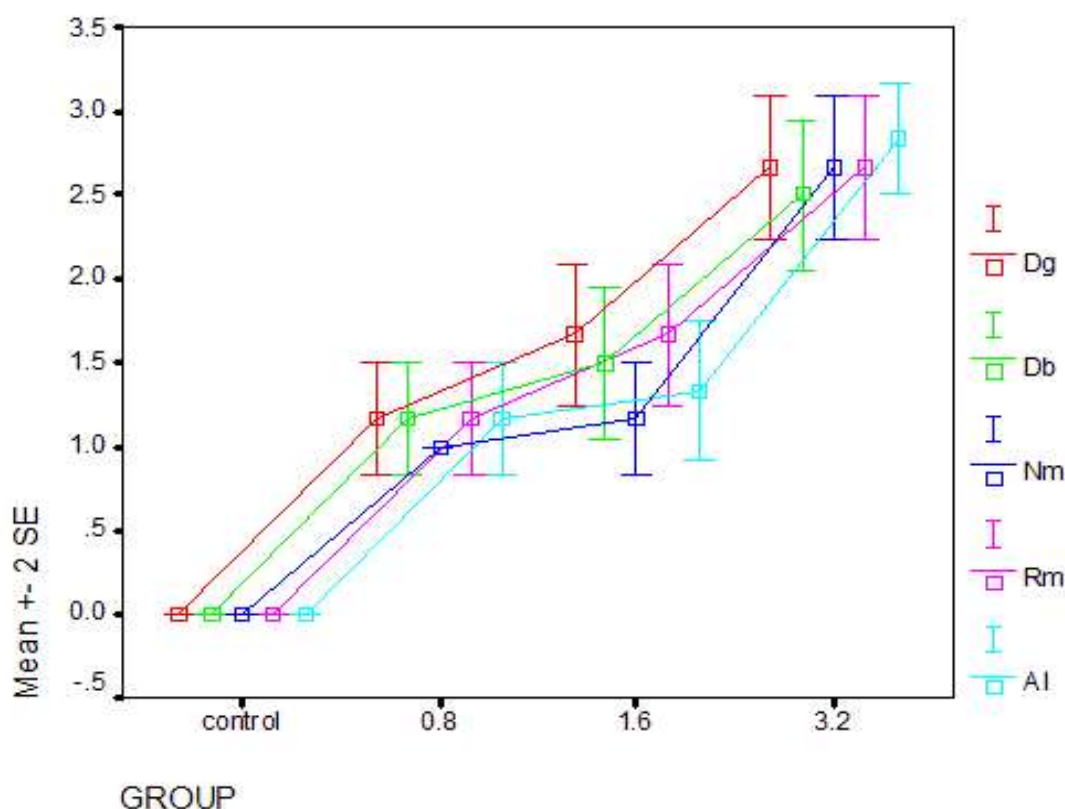


Fig.1. Effect of intra paritonal administration of *Trigonella foenum- graecum* leaves aqueous extract (TGLE) at the indicated doses

Effect i.p.administration of *Trigonella foenum- graecum* leaves aqueous extract (TGLE) at the indicated doses once at 10th day of gestation on the histopathological signs of rat fetus long bone. Dg: Deformation of growth cartilage plate; Db: Deformation of bone collar (thin & thick); Nm: Narrowing of bone marrow cavity; Rm: Reduction of mineralization; Al: Abnormal long bone form. The bars represent the mean ± SEM. for 24 of the rat fetuses. Comparisons were made between control and experimental groups. Data were normal (no changes) in control group (0.00±0.00); n=6.

Fig.2, 3: Effect of intra peritoneal administration of *Trigonella gracum* leaves aqueous extract (TGLE) on long bone structures in rats fetus. Its assess with control group (A) andf TGLE administered group (B, 08, C, 16, D 32 g/kg /day). Overall view of figures (Fig.2A, Fig 3B,C, D) expression qualitative statuses of Mild, Moderate and Severe extract effects, respectively.

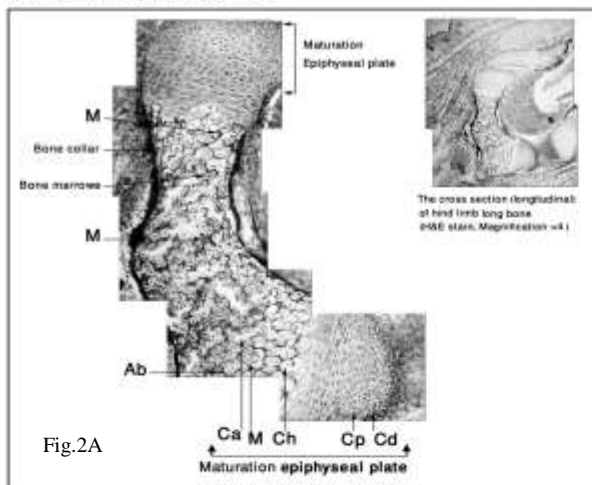


Fig.2: The cross section (longitudinal) of hind limb long bone (H & E stain; Magnification x100). The Histopathological factors express normal formation of long bone in control group (A). Mature epiphyseal cartilage plate is indicated by Cd, Chondroblast differentiation, Cp, Chondrocyte proliferation, Ch, Chondrocyte hypertrophy, M, Mineralization, Ca, Cell apoptosis, Ab, Activity of bone collar osteogenesis.

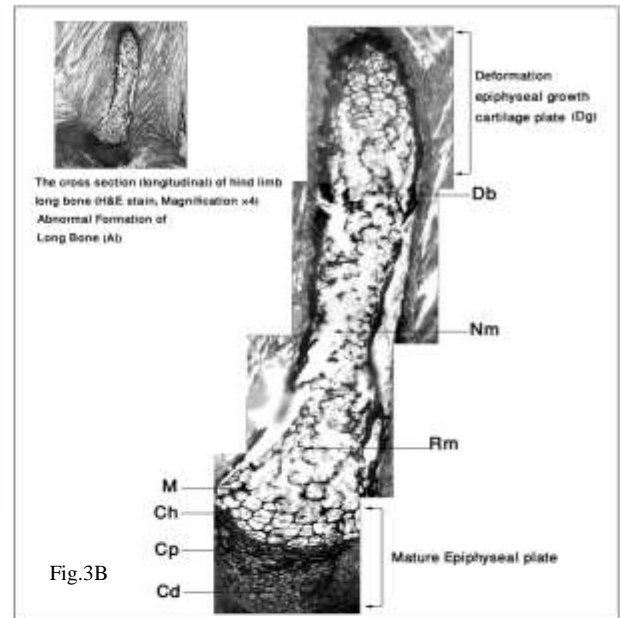


Fig.3B




Fig.3C

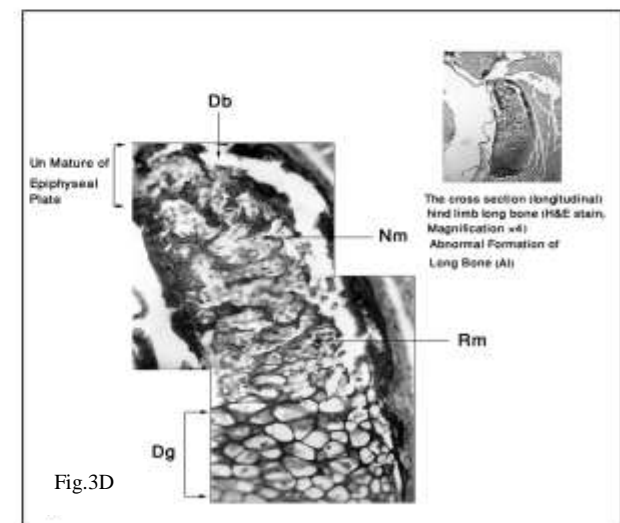


Fig.3D

Fig.3: The cross section (longitudinal) of hind limb long bone (H & E) stain, Magnification x100). The histopathological disorders (due to effect of extract) are indica tive qualitative statuses of extract effect as Dg. Deformation of growth cartilage plate, Db, Deformation in bone collar (thin & thick, Nm, Narrow of bone marrow cavity, Rm, Reduce of mineralization and AI, Abnormal long bone form. Deformation of growth cartilage plate (Dg) as un symmetry between both sides of long bone epiphyseal growth plate, Nm, Db (a few thick) and Rm are observable (B, C, arrows). Abnormal development of hind limb long bone as un matured of epiphyseal plate (Dg) in one side of hind limb long bone. Nm, Abnormal form of long bone (AI) and finally disorder in long bone growth and structure are observable (D, arrows).

DISCUSSION

In the present study, the rat fetuses treated with *Trigonella foenum-graecum* leaves extract (TGLE) exhibited significant osteogenesis dysfunctionality in the growth and structure details of endochondral ossification. This led to an abnormal long bone form (Al) as Deformation of growth cartilage plate (Dg), Deformation of bone collar (Db), Reduction of mineralization (Rm) and Narrowing of bone marrow (Nm). These changes were associated with effected macroscopic parameters such as Bi Parietal Diameter ear to ear of the rat fetuses treated with TGLE (3.2 g/kg/day) comparison to the control group (P=0.039). Also according to the results of the current study, there is a direct relation between the increase of mortality rate and extract dose (data is not presented). But no malformation changes were exhibited in fetuses treated with TGLE. Overall histopathological changes show the applicable dosage that affected histological details of long bone growth and structure in rat fetuses treated with TGLE. Most histopathological changes were mild, mild-moderate and severe in groups treated by different dosages of TGLE (0.8, 1.6 and 3.2 g/kg/day) respectively. Our results show that TGLE led to a clear deformation of growth cartilage plate as dysymmetry between both sides of long bone epiphyseal growth plate and disorder in endochondral ossification. Thus, TGLE causes toxicity effects on pregnant rats specifically during organogenesis stage of their fetuses skeletal organ. It was also supported by previous findings for not using fenugreek during pregnancy because of its potential uterine stimulating properties in animal (Abdo and al-Kafawi 1969). There are evidences indicating that feeding diets containing 30% fenugreek seeds caused a potential anti fertility activity to both female and male rabbits (Kassem *et al.*, 2006). It was obtained that the abnormal fetal development might be the consequences of fenugreek seeds containing an estrogenic activity that disturbed the endometrial lining system and interferes with fetal development (Khare *et al.*, 1983; AL-Hamood and AL-Bayatti, 1995; Elbetieha *et al.*, 1996). There were evidences indicating i.p. administration of the glycosidic extract of fenugreek (*Trigonella foenum-graecum*) leaves induce toxic effects on the CNS, and i.p. administration of lethal doses of the glycosidic extract showed a mild degree of pathological changes in the liver, where early degeneration with mild hepatitis was found (Abdel- Barry and Al- Hakiem, 2000). Thus we suggest, for future studies, to investigate the effect of glycosidic extract on the development of other organs, particularly the nervous system development in rat fetus in comparison with the results of the present study. The extract components of *Trigonella foenum-graecum* have been identified in many studies. It is known to contain flavonoid, nicotinic acid and salicylate. (Javan *et al.*, 1997). Phytochemical studies showed that alkaloids, cardiac glycosides and phenols were present in this extract (Ahmadiani *et al.*, 2000). In addition, flavonoid has been found to have significant apoptosis properties in cancer cells (Amin *et al.*, 2005). Based on the published studies, saponins, fibers and flavonoids seemed to be the most likely candidates eliciting immunostimulating effects (Bin-Hafeez *et al.*, 2003). Many active components of the extract have been obtained, but no study has indicated the toxicity component of the extract causes the same disorders on the histological details of rat fetus long bone. Therefore, we suggest for future investigation to focus on the research of the same components in the extract. Development of the fetal skeleton begins with the condensation of mesenchymal cells in the embryo, which subsequently differentiate into chondrocytes and form the cartilage anlagen of the skeleton. Longitudinal bone growth occurs throughout the transformation of growth plate chondrocytes into bone by a transformation system from cells to calcified bone matrix. There were evidences indicated that prenatal ethanol exposure resulted in a decrease in fetal bone length, which appeared to be a shorter diaphysis and a decrease in the length of the resting zone. Also, prenatal ethanol exposure affected fetal skeletal development which was independent of those on overall fetal growth, and these effects occur even at moderate levels of maternal drinking. Effects of prenatal ethanol exposure on fetal skeletal developmental could potentially increase the offspring's risk of osteoporosis later in life (Simpson *et al.*, 2005; Snow and Keiver, 2007). Also our finds showed that the treatment with TGLE especially (3.2g/kg/day) induced abnormal long bone form and eventually decreased significantly in longitudinal bone growth of the hind limb. It was shown that valproic acid suppressed longitudinal bone growth by inhibiting cartilage formation and accelerating ossification of the growth plate (Wu *et al.*, 2004). A study showed that Jaoga-Yukmiwon (R), a Korean herbal medicine, might promote longitudinal bone growth during the developmental period (Leem *et al.*, 2003). The growth plate consisted of four distinctive histological zones beginning with the resting zone and extending through the proliferative and hypertrophic zones. In the ossification zone, the chondrocytes eventually died and transformed into bone matrix where longitudinal bone growth occurred. There are evidences indicated that effects of several different substances on longitudinal bone growth such as egg yolk proteins (Leem *et al.*, 2004), estrogen (Chagin *et al.*, 2006), BMP-2 (De Luca *et al.*, 2001), catechin of green tea (Chen *et al.*, 2005), caffeine and exercise (Huang *et al.*, 2002). Also a review indicated that regulatory mechanism of food factors is linked to bone metabolism and prevention of osteoporosis (Yamaguchi, 2006), and another review links traditional chinese medicines to bone formation (Wong and Rabie, 2006) so, we suggest that consumption these substances with TGLE concurrently perhaps could have been protected effects on the bone. We

conclude that TGLE in the applicable dosage, without using any other herbal plant concurrently, causes developmental toxicity and adverse effects on cell growth and structure histology details of long bone in rat fetus.

Acknowledgments

We thank the Department of histology and histopathology Laboratory in Tarbiat Moallem University for their support.

REFERENCES

- Abdel-Barry, J.A., I.A. Abdel- Hassan and M.H.H. Al- Hakiem (1997). Hypoglycaemic and antihyperglycaemic effects of *Trigonella foenum-graecum* leaf in normal and alloxan induced diabetic rats. *J. Ethnopharmacol.*, 58:149-155.
- Abdel- Barry, J.A. and M.H.H. Al- Hakiem (2000). Acute intraperitoneal and oral toxicity of the leaf glycosidic extract of *Trigonella foenum-graecum* in mice. *J. Ethnopharmacol.*, 70: 65-68.
- Abdo, M.S. and A.A. Al-Kafawi (1969). Experimental studies on the effect of *Trigonella foenum-graecum*. *Planta Med.*, 17: 14-18.
- Ahmadiani, A., M. Javan, S. Semnanian, E. Barat and M. Kamalinejad (2000). Anti-inflammatory and antipyretic effects of *Trigonella foenum-graecum* leave extract. *J. Ethnopharmacol.*, 75: 283-286.
- AL-Hamood, M.H. and Z.F. AL-Bayatti (1995). Effects of *Trigonella foenum graecum* , *Nerium oleander* and *Ricinus communis* on reproduction in mice. *Iraqi J Sc.*, 36: 425.
- Amin, A., A. Alkaabi, S. AL-Falasi and S.A. Daoud (2005). Chemopreventive activities of *Trigonella foenum-graecum* (Fenugreek) against breast cancer. *Cell Biol Int.*, 29: 687694.
- Basch, E., C. Ulbricht, G. Kuo, P. Szapary and M. Smith (2003). Therapeutic Applications of Fenugreek. *Alternative Medicine Review*, 8: 20-27.
- Bin-Hafeez, B., R. Haque S. Parvez, S. Pandey, I. Sayeed and S. Raisuddin (2003). Immunomodulatory effects of fenugreek (*Trigonella foenum graecum* L.) extract in mice. *Int. Immunopharmacol.*, 3:257-265.
- Chagin, A.S., D. Chrysis M. Takigawa E.M., E.M. Ritzen and L. Savendahl (2006). Locally produced estrogen promotes fetal rat metatarsal bone growth; an effect mediated through increased chondrocyte proliferation and decreased apoptosis. *J Endocrinol.*, 188: 193-203.
- Chen, C.H., M.L. Ho, J.K.Chang, S.H. Hungand and G.J. Wang (2005). Green tea catechin enhances osteogenesis in a bone marrow mesenchymal stem cell line. *Osteoporos Int.*, 16: 2039-2045.
- De Luca, F., K.M. Barnes, J.A. Uyeda, S. De-Levi, V. Abad, T. Palese, V., Mericq and J. Baron (2001). Regulation of growth plate chondrogenesis by bone morphogenetic protein-2. *Endocrinology*, 142:430-436.
- Elbetieha, A., M.H. Al-Hamood and A. Al-Kofahi (1996). Anti-implantation potential of some medicinal plants in female rats. *Arch STD/HIV*.10:181-187.
- Fazli, F.R.Y. and R. Hardman (1968). The spice fenugreek (*Trigonella foenum-graecum* L.) its commercial varieties of seed as a source of diosgenin. *Trop Sci.*, 10: 66-78.
- Huang, T.H., R.S. Yang, S.S. Hsieh and S.H. Liu (2002). Effects of caffeine and exercise on the development of bone: a densitometric and histomorphometric study in young wistar rats. *Bone*, 30: 293-299.
- Javan, M., A. Ahmadiani, S. Semnanian and M. Kamalinejad (1997). Antinociceptive effects of *Trigonella foenum-graecum* leaves extract. *J Ethnopharmacol.*, 58:125-129.
- Al-Aghbari, A., M. AL-Habori and M. Al-Mamary (2006). Evaluation of the potential anti-fertility effect of fenugreek seeds in male and female rabbits. *Contraception*, 73: 301-306.
- Khare, A.K., M.K. Sharma and V.M. Bhatnagar (1983). Evaluation of the potential antifertility effect of fenugreek *Arogya . J. Health Sci.*, 9: 91-93.
- Leem, K., S.Y. Park, D.H. Lee, Y.M. Boo, H.J. Park, J.H. Chung and H. Kim (2003). Effects of Jaoga-Yukmiwon[®], a Korean herbal medicine, on chondrocyte proliferation and longitudinal bone growth in adolescent male rats. *Phytotherapy Res.*, 17: 1113 – 1116.
- Leem, K., M. Kim, H. Kim, M. Kim, Y. Lee and H.K. Kim (2004). Effects of egg yolk protein on the longitudinal bone growth of adolescent male rats. *Biosci. Biotechnol. Biochem.*, 68: 2388-2390.
- Mirhaydar, H. (1994). *Plant Information: plant usage in disease treatment*. Nashre Farhang Islami Press. pp. 303.
- Rajagopalan, M.S. (1998). Fenugreek, what can this herb offer? *Naturally*, 1:1-4.
- Shani, J., A. Gold Schmied, B. Joseph, Z. Abronson and F.G. Sneman (1974). Hypoglycemic effects of *Trigonella faenum graecum* and *Lupinus termis* (Leguminosae) seed and their major alkaloids in alloxan-diabetic and normal rats. *Arch. Int. Pharmacodyn Ther.*, 210: 27-37.

- Sharma, R.D. (1986). Effect of fenugreek seeds and levels on blood glucose and serum insulin response in human subjects. *Nutr Res.*, 6: 1353-1364.
- Simpson, M.E., S. Duggal and K. Keiver (2005). Prenatal Ethanol Exposure Has Differential Effects On Fetal Growth and Skeletal Ossification. *Bone*, 36: 521-532.
- Snow, M.E. and K. Keiver (2007). Prenatal ethanol exposure disrupts the histological stages of fetal bone development. *Bone*, 41:181-187.
- Wong, R.W.K. and A.B.M. Rabie (2006). Traditional Chinese Medicines and Bone Formation—A Review. *J Oral Maxillofac Surg.*, 64: 828-837.
- Wu, S., A. Legido and F. De Luca (2004). Effects of Valproic Acid on Longitudinal Bone Growth. *J Child Neurol.* 19: 26-30.
- Yamaguchi, M. (2006). Regulatory Mechanism of Food Factors in Bone Metabolism and Prevention of Osteoporosis *The Pharmaceutical Society of Japan. Rev.*, 126: 1117-1137.
- Zargari, A. (1992). *Medicinal Plants*. Tehran University Publication. 5th ed. pp.637.

(Accepted for publication July 2010)