

## HISTOPATHOLOGICAL CHANGES IN SKIN OF *JOHNIUS MACULATUS* (SCHNEIDER, 1801) INFECTED WITH PROTOZOAN PARASITE

BUSHRA KHALIL, F.M. BILQEES AND SYED AJAZUDDIN

Department of Zoology Jinnah University for Women, Karachi- 74600, Pakistan  
Adamji Government Science College, Karachi, Pakistan  
E-mail: bushra – juw @ yahoo.com

---

### ABSTRACT

Histopathological changes are described based on observations made on the skin of the fish *Johnius maculatus* infected with an unidentified protozoan. Histological sections were stained with haematoxylin and eosin, dehydrated in graded series of alcohols, cleared in clove oil and xylene and mounted permanently in Canada balsam. Photographs were prepared with Nikon (Optiphot-2) photomicroscope. Protozoan infection severely damaged the skin tissue - common findings were erosion, atrophy, dislocation of muscle fibers, shrinkage and degeneration of muscle fiber which produced large spaces between the muscles fibers. Hyaline degeneration of muscle fibers was also prominent in some sections. Epidermal and dermal layers were separated from each other due to the fiber damage.

**Key Words:** Histopathology, skin, protozoa, fish, *Johnius maculates*, Karachi coast

---

### INTRODUCTION

Protozoa are the most abundant animals in the world in terms of numbers and biomass. Protozoa are important as parasites, symbionts of multicellular animals. There are more than 50000 protozoan species and only a portion of them are parasitic. They are found in all organs of the fish as ecto- and endo-parasites including skin, fins, gills, eyes, kidney, liver, intestine, stomach, spleen, heart and brain. They feed and live on the fish and some even reproduce on the fish. Representatives of all major groups of parasitic protozoa use the external surface of the fish integument as an environment. The protozoan parasites are harmful not only due to their own activity but also because of disseminating bacterial and other infections. Protozoan parasites in fishes damage the surface of the body causing wounds and ulcerations.

Among fishes the common protozoan ectoparasites of fish are *Ichthyophthirius multifiliis* (Fouquet, 1876), *Chilodonella* sp. (Strand, 1928), *Chilodonella piscicola* (Zacharias, 1894), *Chilodonella hexasticha* (Kiernik, 1909), *Cryptocaryon irritans* (Brown, 1951), *Trichodina domerguei* (Wallengren, 1897), *Trichodina* sp., (Ehrenberg, 1838), *Trichodina truttae* (Muller, 1937), *Glossatella* (Buetschli, 1889), *Glossatella glabra* (Roth, 1909), *Tetrahymena corlissi* (Thompson, 1955), *Tetrahymena pyriformis* (Ehrenberg, 1830), *Ichthyodo necator* (Henneguy, 1883), *Piscinoodinium pillulare* (Schaperclaus, 1954), *Oodinium ocellatum* (Brown, 1931), *Amyloodinium limneticum* (Jacobs, 1946), *Plistophora typicalis* (Gurley, 1893) and *Kudoa histolytica* (Perard, 1928).

There are several reports on skin histopathology of marine and fresh water fishes ( Reichenback – Klinke, 1954 ; Lucky, 1970 ; Hines and Spira , 1973 a-b , 1974 a- b ; Paperna , 1980 ; Miyazaki et al., 1986 ; Ferraz , 1998; Awal *et al.*, 2001 ; Vogelbein *et al.* , 2001 ; Cruz – Lacierda and Erazo – Pagador , 2004 ; Zhang , 2004 ; Adeyemo and Agbede , 2008).

### MATERIALS AND METHODS

Seventy fresh specimens of *Johnius maculatus* (Sciaenidae) were collected from Ibrahim Haideri (Korangi creek), Karachi. For histopathological studies pieces of infected skin of the selected fishes were fixed in Bouin's solution for 24 hours, and then washed several times with 70% alcohol to remove as much as possible the yellow colour of the fixative. This material was dehydrated in graded series of ethyl alcohol (70%, 90% and 100%). The pieces of skin were then transferred to Cedar wood oil for 8 to 12 hours. Cedar wood oil was slowly removed by placing these in a mixture of equal amounts of xylol and cedar wood oil and then into pure xylol for 2 to 4 hours. Wax blocks were prepared by standard procedure as described by Bilqees (1995). Thin sections of 6-8 $\mu$  were cut by rotary microtome. Sections were dewaxed, stained with haematoxylin and eosin and mounted permanently in Canada balsam by usual procedure. Photographs of selected portions of the sections were taken with a Nikon (Optiphot - 2) photomicroscope.

## OBSERVATIONS AND RESULTS

Histopathological observations on the infected skin of *Johnius maculatus* indicated severe skin tissue damage. Skin tissue of *Johnius maculatus* showed aberrant conditions including erosion, destruction, separation, dislocation, shrinkage, atrophy and hyaline degeneration of muscles. Protozoans were present in the superficial layers as well as in the deeper layers. In the dermis muscle, fibres were separated from each other. In some sections hyaline degeneration of muscle fibres was obvious. Muscle fibres nuclei were not seen (Fig.1).

Protozoan were scattered on the whole surface and damage skin tissue. Shrinkage of muscle fibres resulted into separation of fibres from each other. Muscle fibres were broken and atrophied. The muscle layers were obviously affected losing the normal morphology. There was no trace of muscle nuclei (Fig.2).

At higher magnification the morphology and architecture of skin appears totally altered with erosion and shrinkage of muscle fibres. Traces of shrunken muscle fibres were present as unidentified masses due to hyaline degeneration of muscle fibres. In some sections cluster of protozoan was obvious between the muscles. These protozoans also caused destruction and shrinkage of muscles fibres. Muscle nuclei were not obvious (Fig.3). The infected skin showed severe damage to both epidermis and dermis. The Protozoans destroyed the structure of skin where protozoan were in large number. They were found at the surface as well as penetrated in the deeper layers (Fig.4).

Hyaline degeneration of muscles and atrophy was a common. Protozoan penetration was prominent between the deeper muscle layers which caused severe tissue damage and necrosis and altered the morphology of skin tissue (Fig.5).

In some sections deformation of skin was more obvious. Large spaces were produced between muscle fibres. Degenerating muscles appeared as masses of homogeneous pink staining material. Erosion and destruction of muscles was clearly seen. Nuclei of muscles can not be traced out (Fig.6).

The outer surface of skin was broken and showed erosion. The total destruction of skin tissue was clearly seen in some sections. Atrophy and shrinkage of muscles fibres was a common abnormality. Here muscles were completely destroyed. Protozoan parasites were present in large number on the whole surface and in deeper tissue (Fig.7).

## DISCUSSION

The histological examination of sections of *J. maculatus* skin infected with parasitic protozoan revealed severe damage to the structure of skin manifested by erosion, separation, dislocation, shrinkage, atrophy and destruction of muscles fibres. The epidermis and dermal layers were affected. The part of epidermis was separated from the dermis due to damage to muscle fiber. Awal *et al.* (2001) also observed separation of epidermis from the dermis. The dermal layer split into parts. The epidermal and dermal parts sloughed off from most regions of the skin of fish *Labeo rohita* and *Cirrhina mrigala* by infection of *Myxosporidium* sp. Hassan (1999) observed the skin of fish *Tilapia* sp. (*Oreochromis niloticus* and *Oreochromis aureus*) infected with *Trichodina* sp. showed sloughing off the epidermal layer; dermis being oedematous. He also observed erosion and ulcer on different parts of the body.

At higher magnification the morphology of skin and its architecture appears totally altered with erosion of muscles fibres. Erosion and destruction of muscles layers were clearly seen in some section of skin. Erosion of surface tissue was observed with large space between the tissues. Cruz – Lacierdia and Erazo – Pagador (2004) also observed erosion on skin of fish *Epinephalus* sp. by the infection of *Cryptocaryon irritans*. Eissa and Abu Mousa (2006) observed erosion on the skin of fish *Oreochromis niloticus* by infection of *Myxosoma* spp. Menasveta (1985) observed small grey erosions on the head, fins, and body of the fish *Ophicephalus striatus* due to bacterial, protozoan and fungal infections.

In few sections of skin, muscular shrinkage and atrophy was apparent. Lucky (1970) observed pathological changes in the skin of fish *Silurus glanis* caused by *Ichthyophthirius* sp. The parasite *Ichthyophthirius* localized between the epidermis and the corium. Disintegration of the fish skin was proportional to the degree of infection. Atrophy of mucous cells occurred especially with migration of the parasites through the skin or membrane of the host. El-Sayed *et al.* (2006) observed atrophy of epidermal cells of skin of fish *Carassius auratus* by infection of *I. multifiliis*. He noted that epidermal cells of skin of *Carassius auratus* around the parasite *I. multifiliis* were atrophied. Atrophy and shrinkage was obvious in all sections. In other sections as well, large spaces were seen between muscle fibres due to shrinkage. Muscles appear in the form of homogeneous pink material. Protozoans were present in the superficial layer of epidermis as well as in dermal layer. In some sections protozoan were present on the whole surface of skin. Protozoans were seen aggregated in several sections. Protozoans are observed in large number where they penetrated in the deeper layers. Penetration caused severe tissue damage and altered the

morphology of skin tissue. Here muscles were completely destroyed. Roubal *et al.* (2009) observed destruction of subsurface cells. Infested surface cells showed dramatic degeneration of the cytoplasm but the nucleus remains intact by the infection of *Ichthyobodo necator* (Henneguy, 1883) on the skin of the Salmonids *Salmo salar* L. and *Salmo gairdneri*

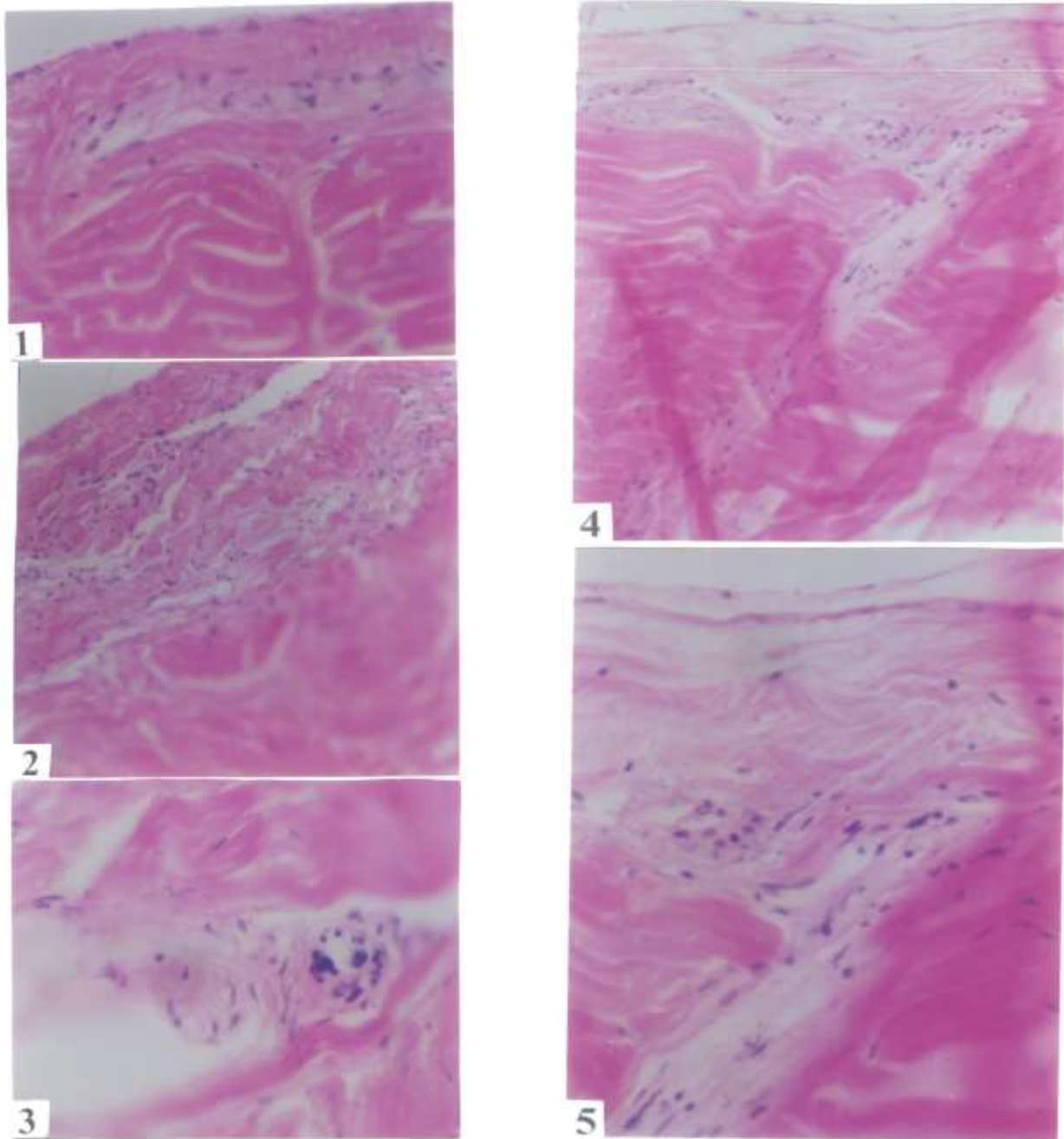


Fig. 1. Section of skin showing protozoan infection on the outer surface. Protozoans can not be seen (X 200).

Fig. 2. Section of skin showing severe damage to skin due to protozoan infection. Note the formation of lesions (X100).

Fig.3. Section at higher magnification showing hyaline degeneration of muscle fibres. A group of protozoans inbetween the degenerating muscles is obvious (X200).

Fig.4. Section of skin showing protozoans at surface and their penetration in the deeper layers (X 100).

Fig.5. Portion of fig.4 enlarged. Section showing details of protozoan penetration and tissue damage. Note the homogeneous appearance of the muscles (X 200).

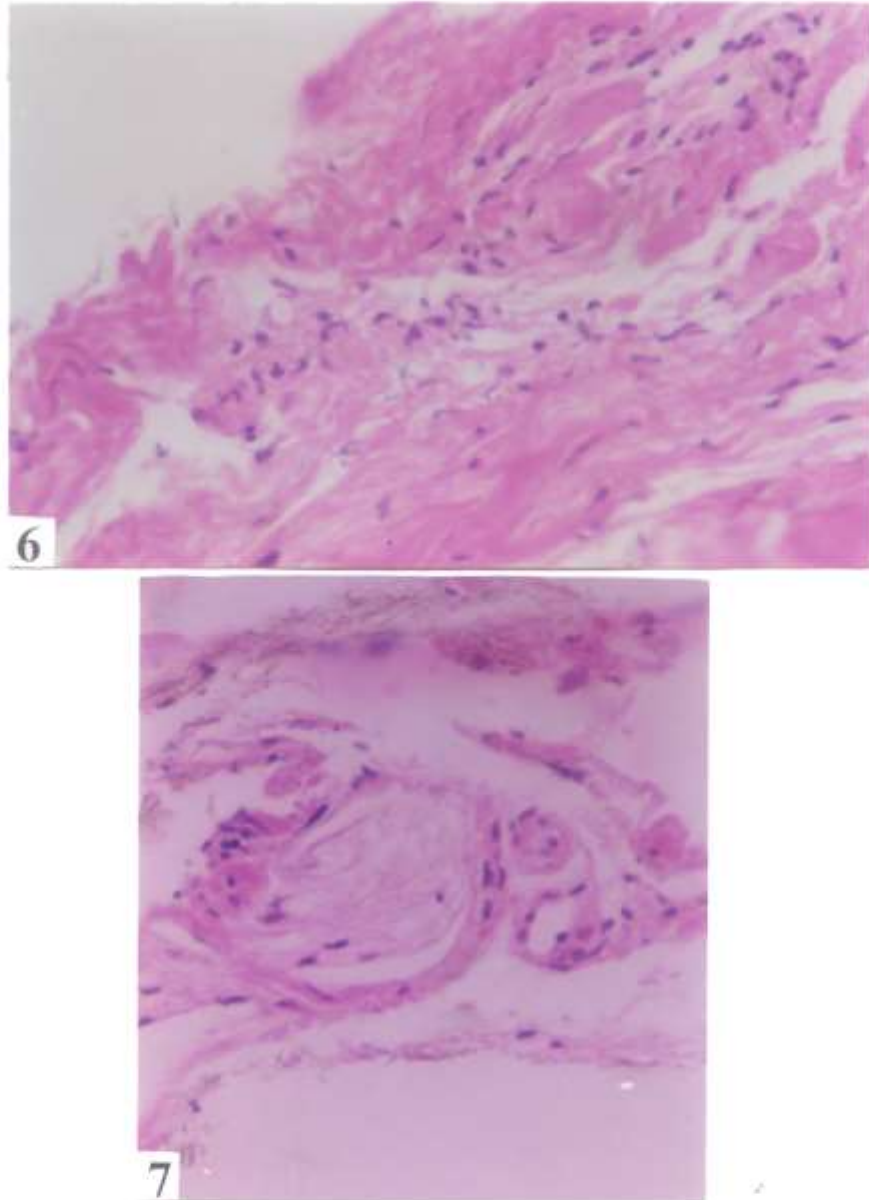


Fig.6. Protozoan infection in the skin of fish *J. maculatus*. Nuclei are obvious in most of the specimens. Large spaces between muscles fibres can be noted. Muscle degeneration and deformation is obvious (X 200).

Fig.7. Section showing severe damage to skin. Several protozoans can be seen throughout the damage tissue. Outer surface and deeper layers of skin are also affected (X 200).

During the present observations some sections indicated dissolution and disintegration of tissue. Lucky (1970) observed rhizoids of *Oodinium pillularis* penetrated deeply into the epidermis. The epidermal cells were destroyed. The destroyed cells around the rhizoids represent a zone of about 0.010 - 0.14 mm on the skin of *Colisa lalia*. Cruz – Lacierdia and Erazo – Pagador (2004) also observed disintegration in the affected tissue of skin of Grouper fish due to *Amyloodinium sp.* infection. During the present observations some sections indicated dissolution and disintegration of tissue. Cruz – Lacierdia and Erazo – Pagador (2004) also observed disintegration in the affected tissue of skin of *Epinephalus sp.* by the *Amyloodinium sp.* infection .

Ferraz (1998) observed extensive epidermal erosion on the skin of fishes *Corydoras spp.* and *Brachis splendens* by trophont of *Piscinoodinium sp.* Each attached trophont appeared to be damaging 3 to 4 epithelial cells on the surface of epidermis and due to which cavities were formed enclosing one or more trophont or empty.

The muscle fibres were adversely affected and shrunken. The muscle fibres were altered and spaces were produced due to shrinkage and atrophy. Hyaline degeneration also occurred and muscles appeared as masses of homogeneous pink staining material. Bacterial infection has been described by Kumar (1986). He observed a mixed infection of protozoan parasite *Myxosporidian sp.* and a bacterium *Aeromonas hydrophila* in the fish *Catla catla*. The pathological changes have shown the sloughing off epidermis, raising of scales, superficial ulceration and haemorrhage. The basic patterns of skin damage observed during the present studies are more or less similar as described by other worker but hyaline degeneration was more prominent in the muscles of fish under study.

## REFERENCES

- Adeyemo, A. O. and S.A. Agbede (2008). Histopathology of Tilapia tissues harbouring *Clinostomum tilapiae* parasites. *African J. Biomed. Res.*, 11: 115-118.
- Awal, M. A., K.J. Begum, K. J. Chandra, G.U. Ahmad and M. Kurohmaru (2001). Myxosporidian infection of gills and skin among carp from nursery ponds in Bangladesh : histopathology. *Vert. Arhiv.*, 71( 5): 265-276.
- Bilqees, F.M. (1995). Histopathology of the liver of *Hilsa ilisha* (Ham.). *Proc. Parasitol.*, 19: 1-20.
- Brown, E. M. (1931). Note on a new species of dinoflagellate from the gill and epidermis of marine fishes. *Proc. Zool. Soc. London* , 1: 345-346.
- Brown, E. M. (1951). A new parasitic protozoan , the causal organism of a white spot disease in marine fish *Cryptocaryon irritans* gen and sp.n. *Agenda of Scientific Meetings of the Zoological Society. London*, 1950, 11: 1-2.
- Cruz – Lacierda, E.R. and G.E. Erazo – Pagador (2004). Parasitic disease. Diseases of cultured Grouper. *Southern Asian Fisheries Development Center Aquaculture Department , Iloilo , Philippines*, 201: 211-217.
- Eissa, A.E. and I.M.K. Abu Mousa (2006). A contribution of Myxosoma infection in cultured *Oreochromis niloticus*. *Nature and Science*, 4 (4): 40-47.
- Elsayed, E.E, N. Ezz El- Dien and A.M. Mahmoud (2006). Ichthyophthiriasis: various fish susceptibility or presence more than one strain of parasite. *Nature and Science*, 4(3): 5-13.
- Ferraz, E. and C. Sommerville (1998). Pathology of *Piscinoodinium sp.* (Protozoa : Dinoflagellidae ) , Parasites of the ornamental fresh water cat fishes *Corydoras spp.* and *Brochis splendens* ( Pisces : Callichthyidae) Dis. *Aquat. Org.*, 33: 43-49.
- Fouquet. (1876). Ichthyophthiriasis is caused by *I. multifiliis* belong to family Orphryogaenidae. *Arch. Zool. Exp.*, 5: 159-165.
- Hassan, M.A.H. (1999). Trichodiniasis in farmed freshwater *Tilapia* in Eastern Saudi Arabia. *J.KAU: Mar. Sci.*, 10: 157-168.
- Hebrank, M.R. (1980). Mechanical properties and locomotor functions of eel skin. *Biol. Bull.*, 158: 58-68.
- Henneguy, L. F. (1883). Sur un infusoire flagelle ectoparasite des poissons. *C. R. Acad. Sci.*, 96: 658-660.
- Hines, R.S. and D.T. Spira (1973a). Ichthyophthiriasis in the mirror carp *Cyprinus carpio* (L).I. causes of infection. *J. Fish Biol.*, 5: 385-392.
- Hines, R.S. and D.T. Spira (1973b). Ichthyophthiriasis in the mirror carp.11. Leucocyte response. *J. Fish Biol.*, 5: 527-534.
- Hines, R.S, and D.T. Spira (1974a). Ichthyophthiriasis in the mirror Carp *Cyprinus Carpio* (L.). 111. Pathology. *J. Fish Biol.*, 6: 189-196.
- Hines, R.S. and D.T. Spira (1974b). Ichthyophthiriasis in the mirror carp *Cyprinus Carpio* (L.). 1V. Physiological dysfunction. *J. Fish Biol.*, 6: 365-371
- Jacobs, D.L. (1946). A new parasitic dinoflagellate from fresh water fish . *Trans. Am. Microsc. Soc.*, 65 (1): 1-17.

- Kiernik, E. (1909). *Chilodon hexustichus* n. sp., ein-auf Susswasserfischen Parasitierendes Infusorium, nebst Bemerkungen Uber Vakuolen, Haut bildung and Zellteilung. *Bull. Intern. Acad. Sci. Cracow cl. Sci. Math. Nat.*, 1: 15-32.
- Kumar, D., B.K. Mishra, B .K. and R.K. Dey (1986). *Dropsy of mixed aetiology in Catla catla ( Ham.)*. Fisheries and Aquaculture Department India. pp. 1-7.
- Lucky, Z. (1970a). Localization of parasites and pathological changes with Ichthyophthiriasis of the sheath fish (*Silurus glanis*). *Acta. Vet. Brno., Suppl.*, 1: 39-49.
- Lucky, Z . (1970b). Pathological changes with Oodinirosis of aquarium fish. *Acta. Vet. Brno. Suppl.*, 1: 67- 73.
- Menasveta, P. (1985). Current fish disease epidemic in Thailand. *J. Sci. Soc. Thailand*, 11: 147-160.
- Miyazaki, T., W.A. Roger and J.A. Plumb (1986). Histopathological studies on parasitic protozoan diseases of the channel cat fish in the United States. *Bull. Fac. Fish., Mie Univ.*, 13: 1- 9.
- Perard, C. (1928). Su rune maladie du maquereau (*Scomber scomber* L.) due a une Myxospridie : *Chloromyxum histolyticum* n. sp. *C R Acad Sci Paris*, 186: 108-110.
- Rechenbach – Klinke, H. (1954). Untersuchungen uber die bei fischen durch parasiten hervorgerufenen zysten and deren wirkung den wirstkorper = “Zeitschrift fur fisherei und deren Hilfswissenschaften”. 3: 365-636.
- Roubal, F. R., A.M. Bullock, D. A. Robertson and R.J. Roberts (2009). Ultrastructural aspects of infection by *Ichthyobodo necator* (Henneguy, 1883) on the skin and gills of salmonids *Salmo salar* L. and *Salmo gairdneri* Richardson. *J. Fish. Dis.* 10(3): 181-192.
- Schaperclaus, W. (1954). *Handbuch der Fischkrankheiten*. Akademie verlag, Berlin. 708 pp.
- Strand, E. (1928). Miscellanea nomenclatorica zoologica et palaeontologica 1-11. *Arch Naturgesch.* 92(A8) (year 1926): 30-75.
- Thompson, J. C. Jr. (1955). Morphology of a new species of *Tetrahymena*. *J. Protozool.* 2(Suppl.) : (Abstract 66).
- Vogelbein, W. K., J.D. Shields, L.W. Hass, K.S. Reece and D.E. Zwerner (2001). Skin ulcer in Esturine fishes : A comparative pathological evaluation of wild and laboratory – exposed fish. *Enviromental Health Perspectives*, Supplements 5, 109: 1-8.
- Wallengren, H. (1897). Zur Kenntnis der Gattung *Trichodina* Ehrbg. *Biol. Central Bl Bd.* 17: 55-65.

(Accepted for publication September 2010)