

## ECHINOCOCCOSIS OF BONE - A RARE CASE STUDY

Samar Sajjad<sup>1</sup>, Nasira Khatoun<sup>1\*</sup>, Arsalan Ahmed<sup>2</sup>, Aly Khan<sup>3</sup> and Samina Waheed<sup>1</sup>

<sup>1</sup>Department of Zoology, University of Karachi, Karachi-75270, Pakistan

<sup>2</sup>Histopathology Department, Aga Khan University Hospital, Karachi, Pakistan

<sup>3</sup>CDRI (PARC), University of Karachi, Karachi-75270 Pakistan

\*Corresponding author's email: nasiraparvez.uok@gmail.com

---

### ABSTRACT

Hydatid cyst is a occasional source of sudden death, with only a few cases being reported in the clinical literature. The purpose of this study is to present a rare case of hydatid infection in woman complaining pain in thighs and suspecting osteomyelitis/tuberculosis. The X-ray revealed that the patient had cystic lesion. The removed lesion was sent to Aga Khan Laboratory for histopathological evaluation where on microscopy it was found to be hydatid cysts of bone of various sizes. Histopathological study of bone presented a homogeneous necrotic area, situated on generalized dystrophic background.

**Key-words:** Lesion, Hydatid cyst, Bone, Echinococcosis, Histopathology.

---

### INTRODUCTION

Echinococcosis is an evolving zoonotic infection and has significant public importance caused by a larval stage of cystic metacestode of *Echinococcus*. Up till now four species are recognized with known zoonotic infections while 2 species *Echinococcus shiquicus* in Tibetan foxes and *Echinococcus felidis* in African lions of unknown significance have also been discovered on which further work is needed to be done (Arik *et al.*, 2015). Hydatid infection is becoming more common in underdeveloped countries particularly in sheep grazing areas. Hydatid cyst of liver, lungs and kidneys are being reported in elevating pattern yearly, while it has been infrequently reported in bone, spleen, breasts and brain, etc.

In osseous characteristic clinical findings nonappearances and image, X-ray or CT features are similar to those of tuberculosis, metastases and giant cell tumour or bone cysts. Diagnosis is confirmed after surgical excision of cyst by histology. Chemotherapy followed by radical excision is the treatment of choice.

Domestic animals serve as intermediate hosts with no sign of disease and the main reservoir for the disease of humans (Eckert and Deplazes, 2004; Abdel-Baki *et al.*, 2018).

Canda *et al.* (2003) reported only 1.25% of bone (left tibia) infected with echinococcosis while 3.75% in vertebrae in Western Turkey while Keser (2017) reported approximately 0.2-0.5% involvement of bone. Involvement of femur has been reported in 32 year male and in 43 year male through radiograph of hip (Kumar *et al.*, 2000; Pathania *et al.*, 2000).

The hydatid cyst consists of three layers: The outer layer forming a fibrous layer of host cells called pericyst. The middle is acellular laminated layer that permits as a channel of nutrients and the third inner germinal layer, where the scolices are formed latter both forming an endocyst, although the acellular laminated membrane is occasionally referred to as the ectocyst. In the present study a forty five year old female complaining of constant thigh pain visiting Aga Khan Hospital, Karachi. The X-ray obtained showed cystic lesion of the femur which after surgery was sent for histopathology.

Although earlier examination had suspected that there is osteomyelitis/tuberculosis. Surgery was planned for removal of lesion and sent to histopathological laboratory for diagnosis.

### MATERIALS AND METHODS

For histopathological study of infected bone with *Echinococcus*, soft tissue and bone pieces measuring 4×3 cm nibbled from infected area were send to Parasitology Laboratory and processed according to Kiernan (2002). The specimens were stored in 70% ethanol and later transferred to 10% buffered formalin. The soft tissue and bone section was dehydrated and embedded in paraffin wax. The blocks were sectioned at 4-6 µm, placed on glass slide and stained with Harris haematoxylin and eosin (H & E) and then viewed under a Nikon microscope. Special stain PAS (Periodic Acid Schiff) was used which highlights the lamellated layers of hydatid cyst.

Representative pictures were taken with attached digital camera at various magnifications and stored in memory disc for future reference.

## RESULTS

We encountered presence of lamellated acellular refractile layer in between the bone trabeculae (Fig. 1). The presence of cyst incites formation of adventitial layer in periosteum and may forms confluent daughter cyst. Histological examination reveals fibrocollagenous tissue pieces exhibiting granulomatous inflammation.

Outer cystic layer comprises of fibro collagenous tissue with moderate granulomatous reaction. Along with histocytes multicellular giant cells are also observed in intertrabecular space (Fig. 2). The lamellated layer obvious which were characteristic of *Echinococcus* hydatid infection. Protoscolices were not obvious in the present study (Fig. 3).

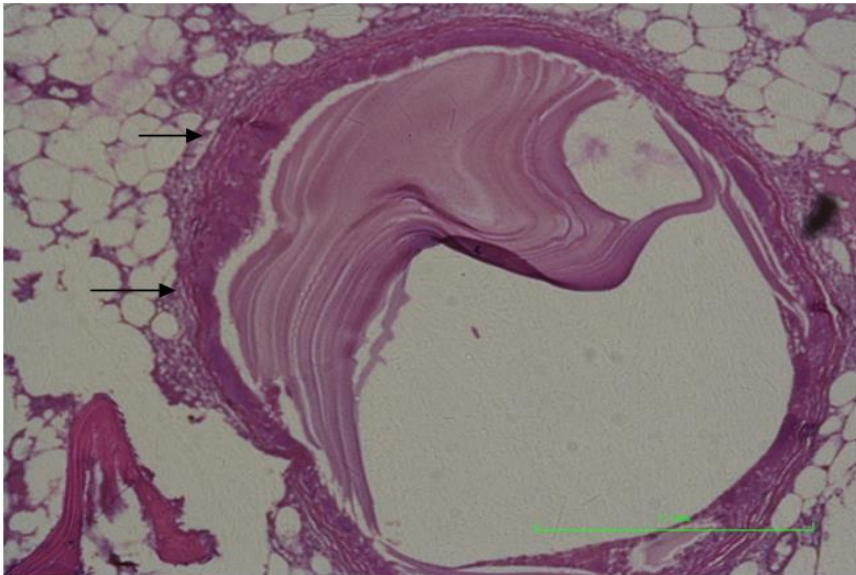


Fig. 1. A part of lamellated layer (arrow) in between bony trabeculae (20 X).

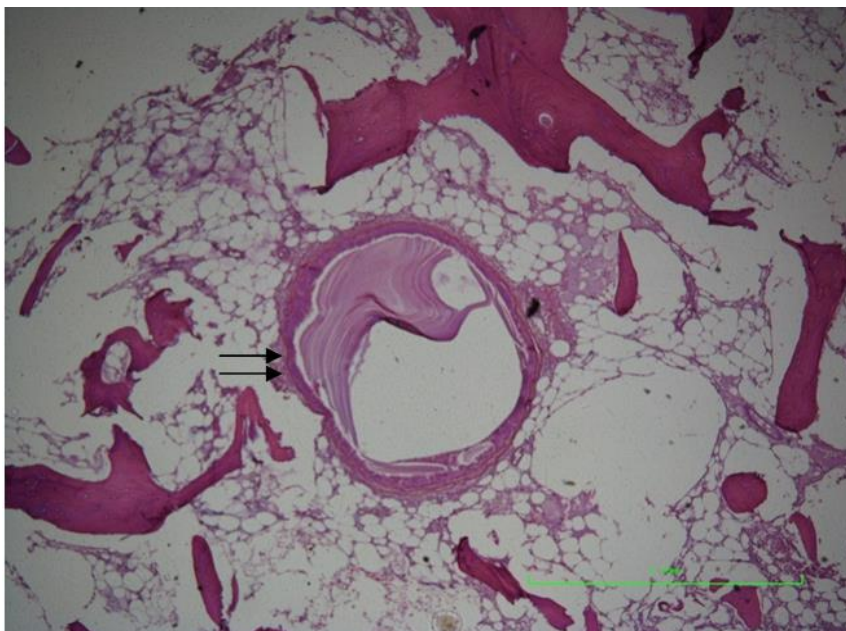


Fig. 2. A fragment of lamellated layer in intertrabecular space showing surrounding granulomatous reaction (arrows) (100 X).

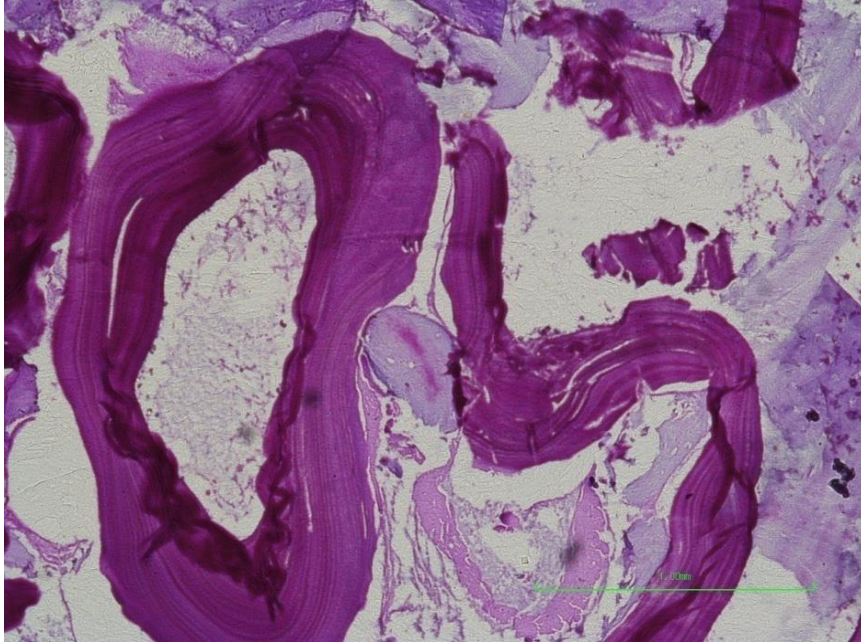


Fig. 3. Periodic Acid Schiff (PAS) stain highlighting the characteristic hydatid layer (100 X).

## DISCUSSION

Echinococcosis is cause of infection in about 2-3 million people around the world. Cystic *Echinococcus* prevalence varies among 1-7% as per community studies while incidence rates ranges from 0-32 cases per 100,000 in hospital based studies. This is more common in women and its frequency increases with age (Budke *et al.*, 2013).

The disease can affect any organ. The most affected organ is the liver followed by the lungs, muscles, bones, kidney, brain and spleen. Diagnosis in bone is rather difficult, hydatid cysts with bone involvement encompass about 3% altogether of disease (Hepgul *et al.*, 2010). Spine is most common location infecting 50% of cases. Hydatid disease of bone typically remains asymptomatic until it causes any malformation or fracture due to advancement of disease. Escalating cystic appearance and slow changes might bear a resemblance to tumor formation (Canale and Beaty, 2011). Complete surgical abolition is seldom possible because localization marks the slow progression of the parasite into bone tissue to an instant diffuse, invasion process (Zlitni *et al.*, 2001). Extra osseous proliferation may lead to calcification of cyst (Ogut *et al.*, 1992).

Ingestion of parasite can be through water or food contaminated with faeces of definitive host. Proper cooking and adequate deworming of pet can prevent disease from transmission. Since sheep are a potential source of hydatidosis transmission to dogs and the continuation of its life cycle in a number of countries. It is thus suggested that to initiate proper regulation of the slaughtering process which include proper disposal of offal so as to minimize transmission of cysts along with treatment of wandering dogs. Hydatid cyst of disease is generally incurable and have high rates of reoccurring. It is suggested that hydatid disease of bone should be taken seriously as a differential diagnosis in osteolytic lesion of bone as suggested by Babitha *et al.* (2015). Earlier, only surgery was the treatment as anthelmintic drugs were rare. Combination of benzimidazolic drugs namely albendazole and mebendazole are the only antihelmintics effective against cystic echinococcosis and are well tolerated. Finally in order to avoid complication early treatment is recommended for echinococcosis of bone (Liang *et al.*, 2014).

## REFERENCES

- Abdel-Baki, A.A.S., E. Almapki and S. Al-Quraishy (2018). Prevalence and characterization of hydatidosis in Najdi sheep slaughtered in Riyadh city, Saudi Arabia. *Saudi Journal of Biological Sciences*, (<http://doi.org/10.1016/j.sbs.2018.04.011>). Article in press.
- Arik, H.Q., M. Arican, N.K. Cetin and U. Sarp (2015). Primary Intraosseous Hydatid Cyst of Femur. *Iranian Red Crescent Medical Journal*, 17(2): e21070. <http://doi.org/10.5812/ircmj.21070>.
- Babitha, F., P.V. Priya and U. Poothiode (2015). Hydatid cyst of bone. *Journal of Med. Microbiol.*, 33: 442-444.

- Budke, C.M., H. Carabin, P.C. Ndimubanzi, H. Nguyen, E. Rainwater, M. Dickey, R. Bhattarai, O. Zeziulin and M.B. Qian (2013). A systematic review of the literature on cystic echinococcosis frequency worldwide and its associated clinical manifestations. *Am. J. Trop. Med. Hyg.*, 88(6): 1011-1027.
- Canale, S.T. and J.H. Beaty (2011). In: Basbozkurt, M. Yildiz, C. editors. *Campbells Operative Orthopaedics: Sun medical book house*. Istanbul. pp. 4664.
- Canda, M.S., M. Guray, T. Canda and H. Astarioglu (2003). The pathology of Echinococcosis and the current Echinococcosis problem in western Turkey (A report of Pathologic features in 80 cases). *Turk. J. Med. Sci.*, 33: 369-374.
- Eckert, J. and P. Deplazes (2004). Biological, epidemiological and clinical aspects of echinococcosis, a zoonosis of increasing concern. *Clin. Microbiol. Rev.*, 17: 107-135.
- Hepgul, G., D. Tihan, P. Kocael, Y. Dogan, T. Ozturk and A. Cihan (2010). [Case report: primary splenic hydatidosis]. *Turkiye Parazitoloji Dergisi.*, 34(3): 184-186.
- Keser, S.H., A. Selek, D. Ece, C.C. Barisik, S. Sensu, G.G. Gecmen, S.S. Erhan, S.C. Kokten, N.O. Barisik and A.E. Gul (2017). Review of hydatid cyst with focus on cases with unusual locations. *Turkish J. Pathol.*, 33: 30-36.
- Kiernan, J.A. (2002). Freezing and fixation. Chapter 8 In: *Microscopy and histology for molecular biologists: A user's guide*, ed. Kiernan, J.A. and Mason, J.G. London: Portland Press.
- Kumar, N., M.S. Gulati and H.L. Nag (2000). MR appearances in a case of femoral echinococcosis. *Skeletal Radiology*, 29: 235-238.
- Liang, Q., H. Wen, A. Yunus, Z. Tian, F. Jiang and X. Song (2014). Treatment experiences of pelvic bone hydatidosis. *International Journal of Infectious Diseases*, 18: 57-61.
- Ogut, A.G., K. Kanberoglu, A. Altug and O. Cokyuksel (1992). CT and MRI in hydatid disease of cervical vertebrae. *Neuroradiology*, 34(5): 430-432.
- Pathania, V.P., S. Kakkar and J. Sikdar (2000). Hydatid disease of femur. *Medical Journal of Armed Forces of India*, 56: 75-76.
- Zlitni, M., K. Ezzaouia, H. Lebib, M. Karray, M. Kooli and M. Mestiri (2001). Hydatid cyst of bone: diagnosis and treatment. *World Journal of Surgery*, 25(1): 75-82.

(Accepted for publication September 2019)